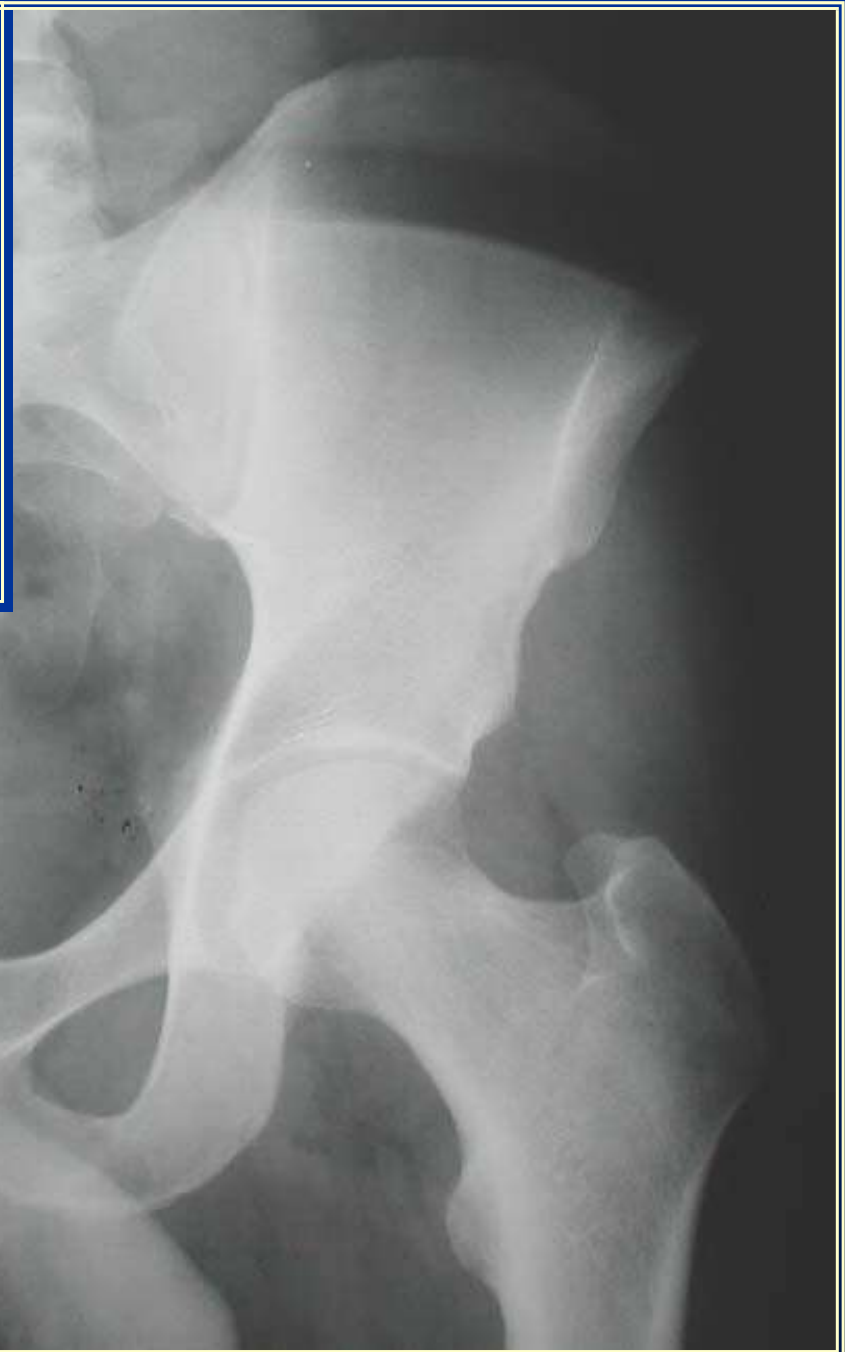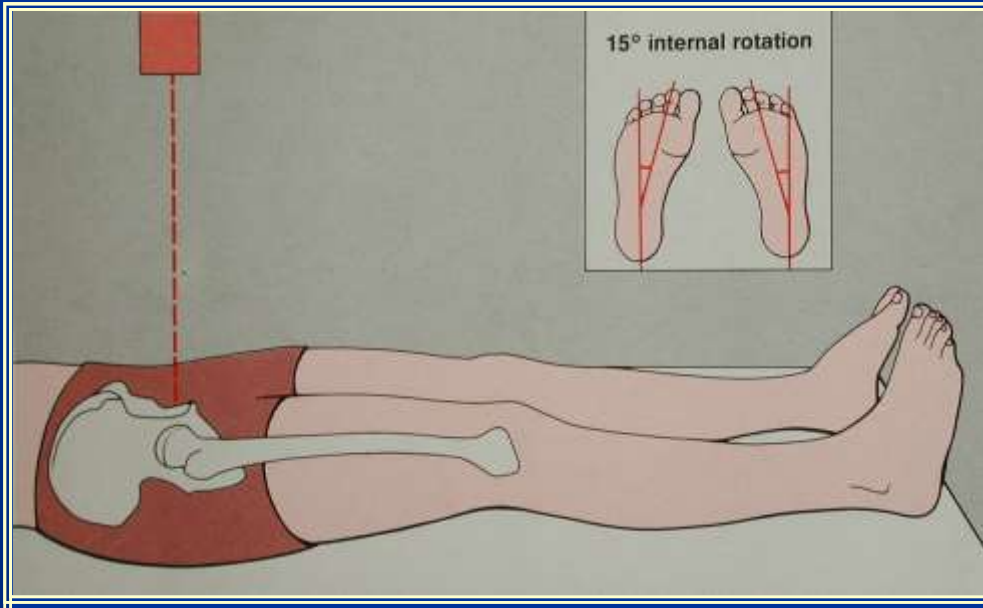
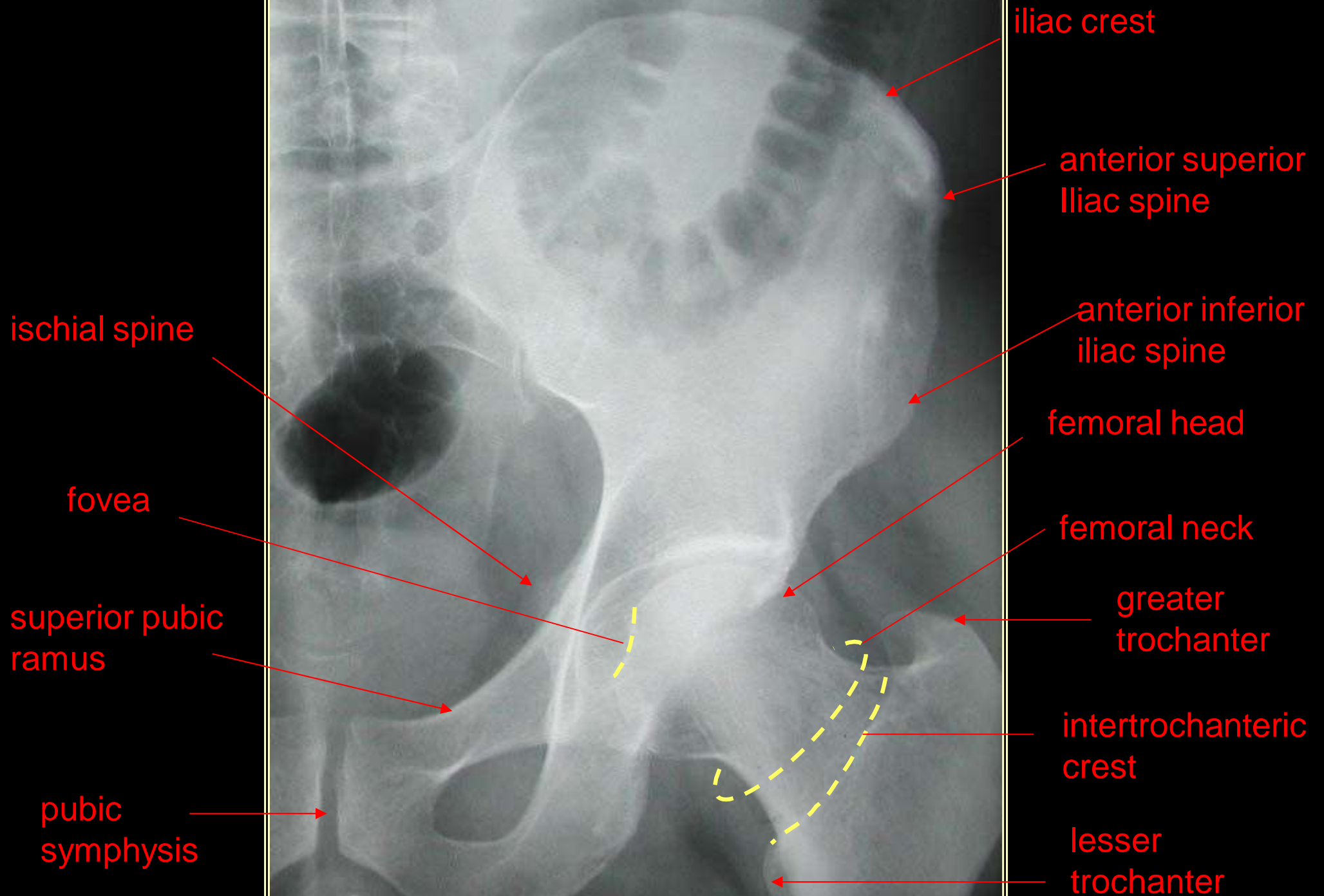


Radiology of the Lower Limb



Anteroposterior View of the Hips





superior acetabular rim

ischium

ischial tuberosity

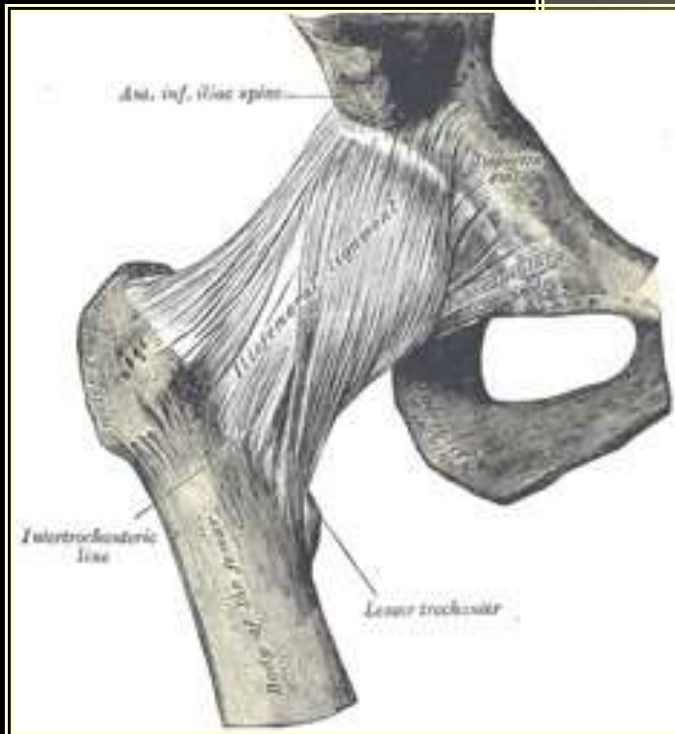
obturator foramen

ilium

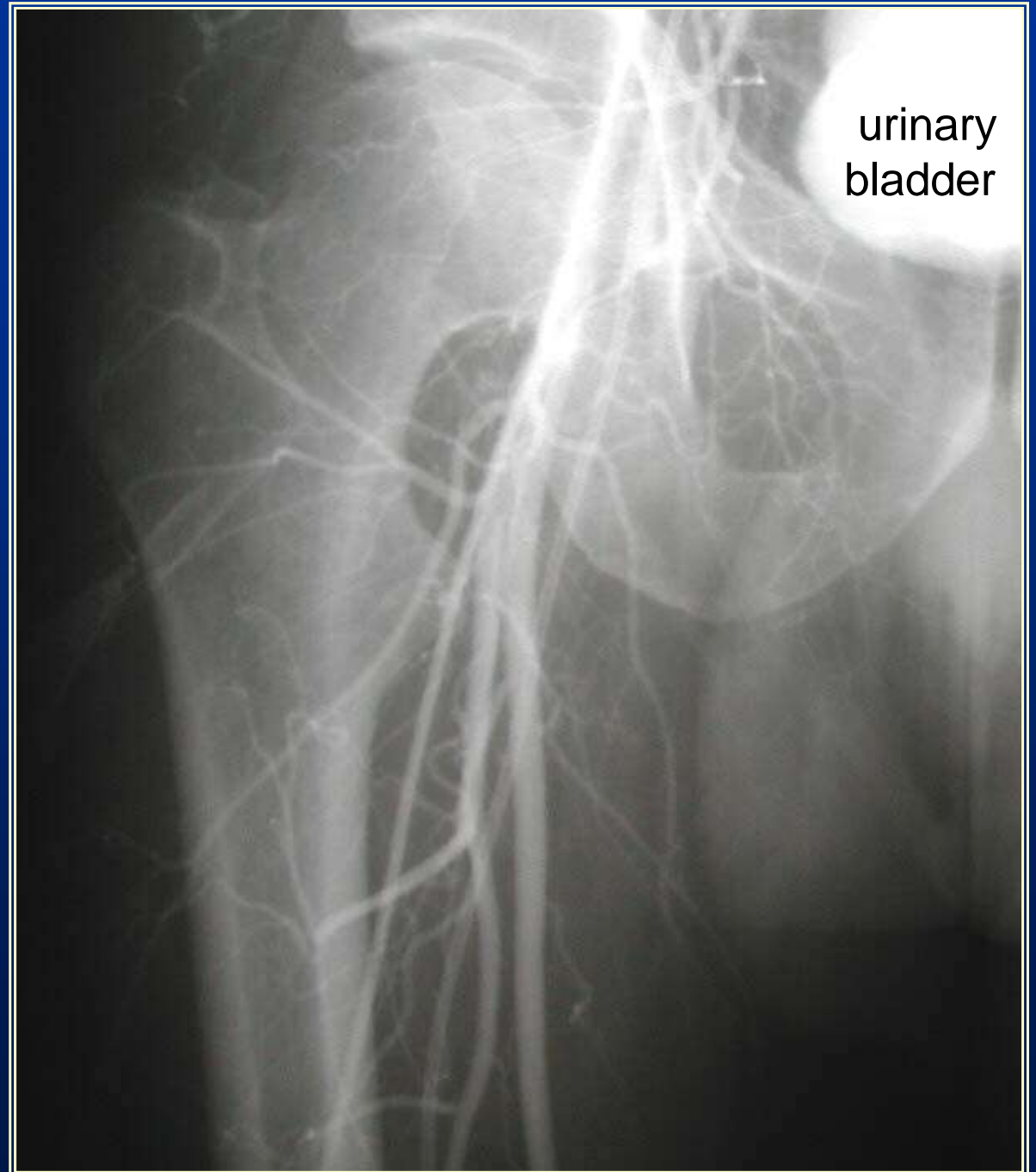
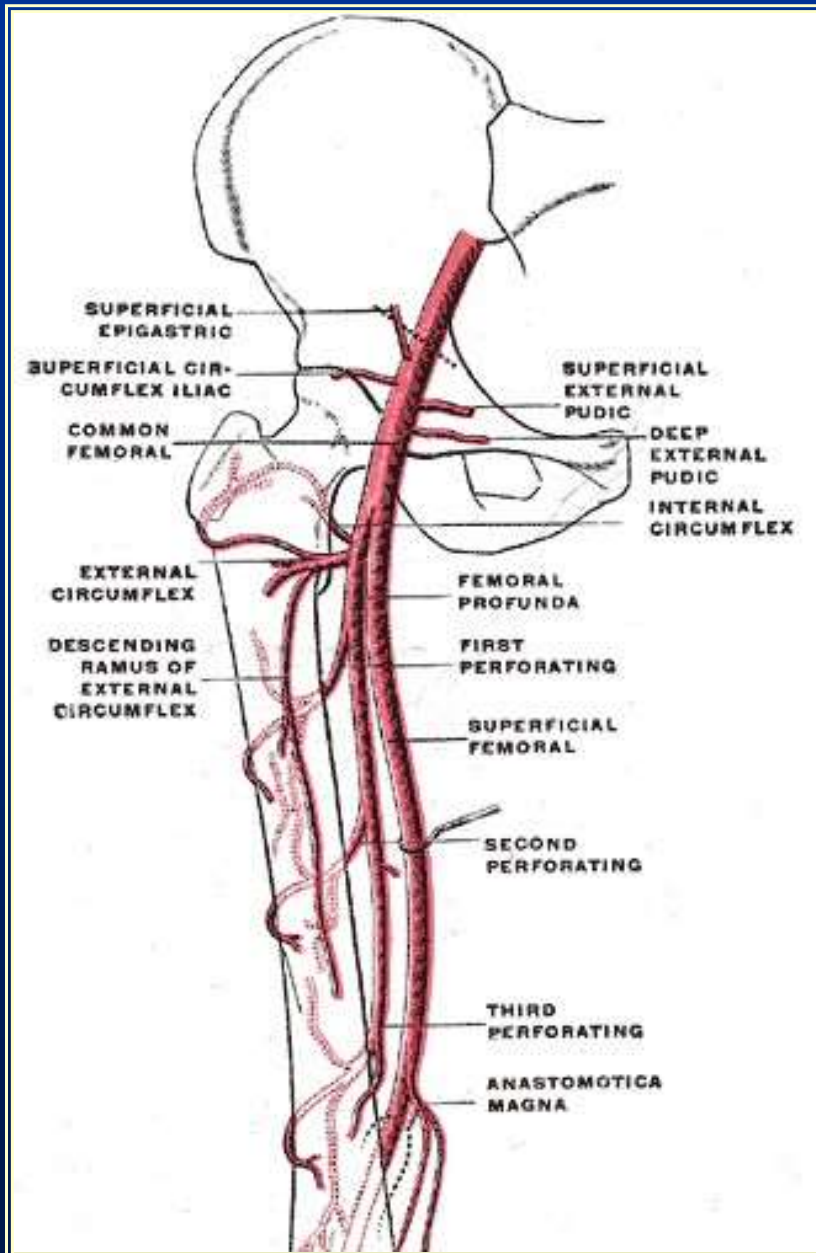
pubis

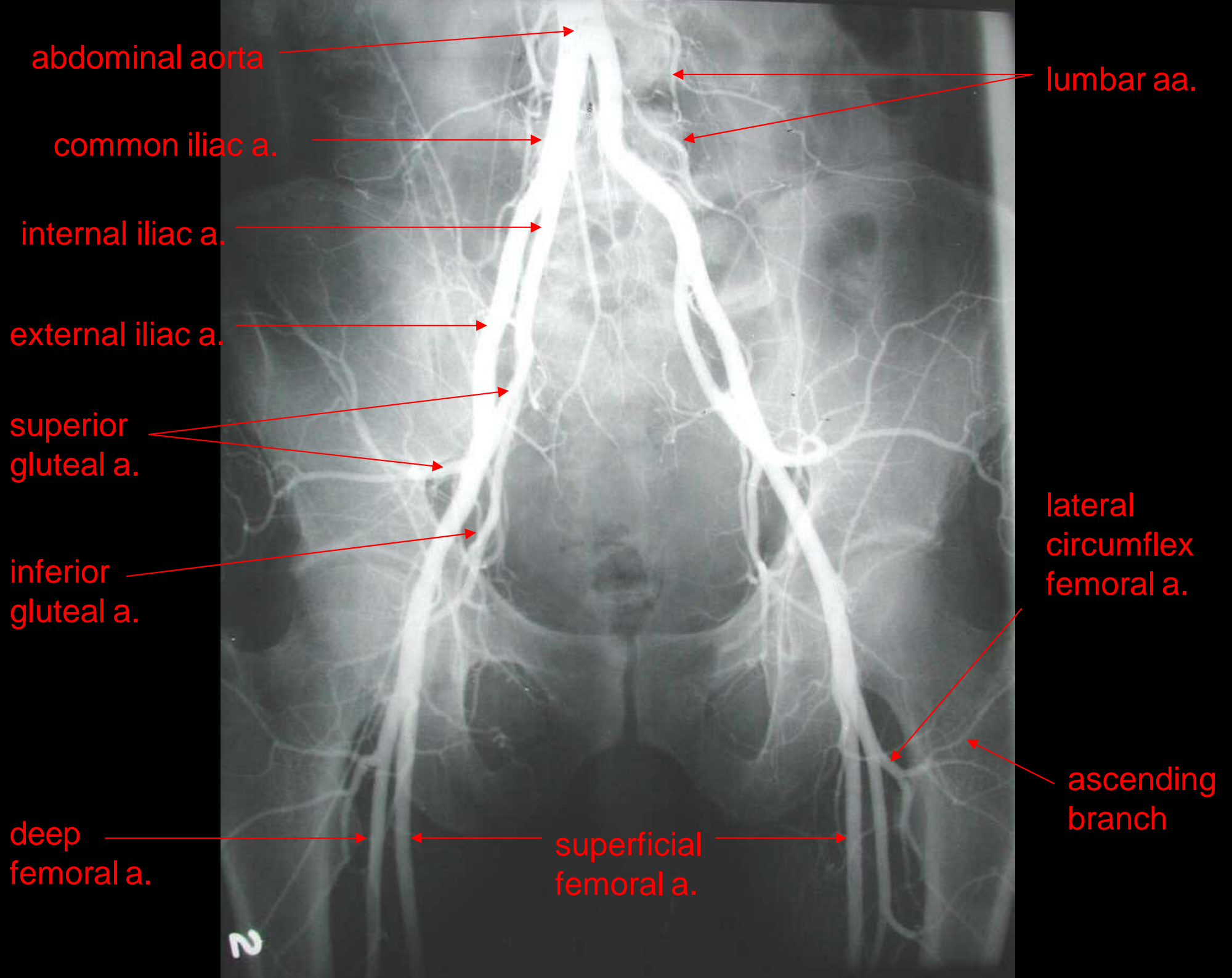
inferior pubic ramus

femoral shaft



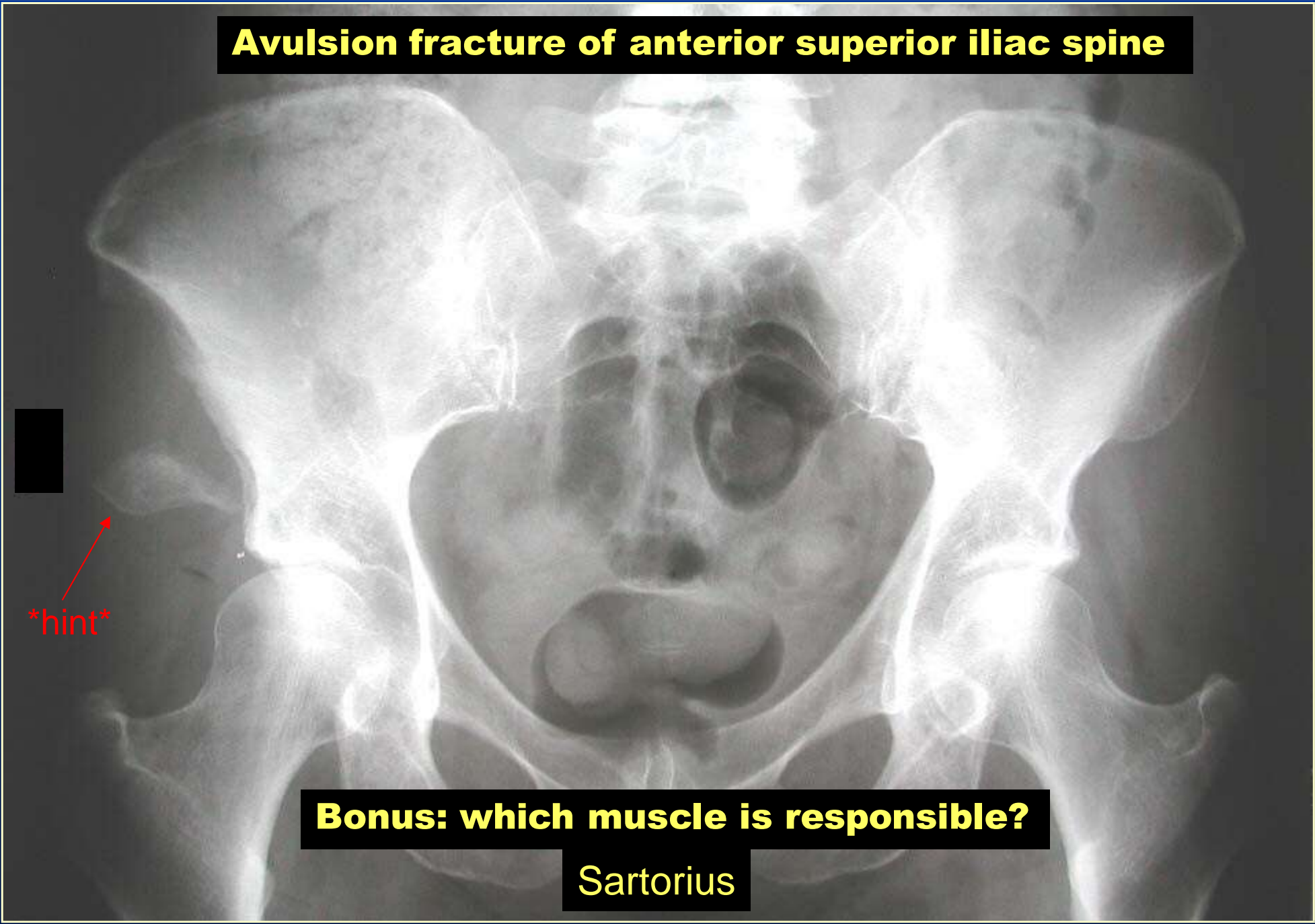
Femoral Arteriogram





What's Wrong With This Hip?

Avulsion fracture of anterior superior iliac spine

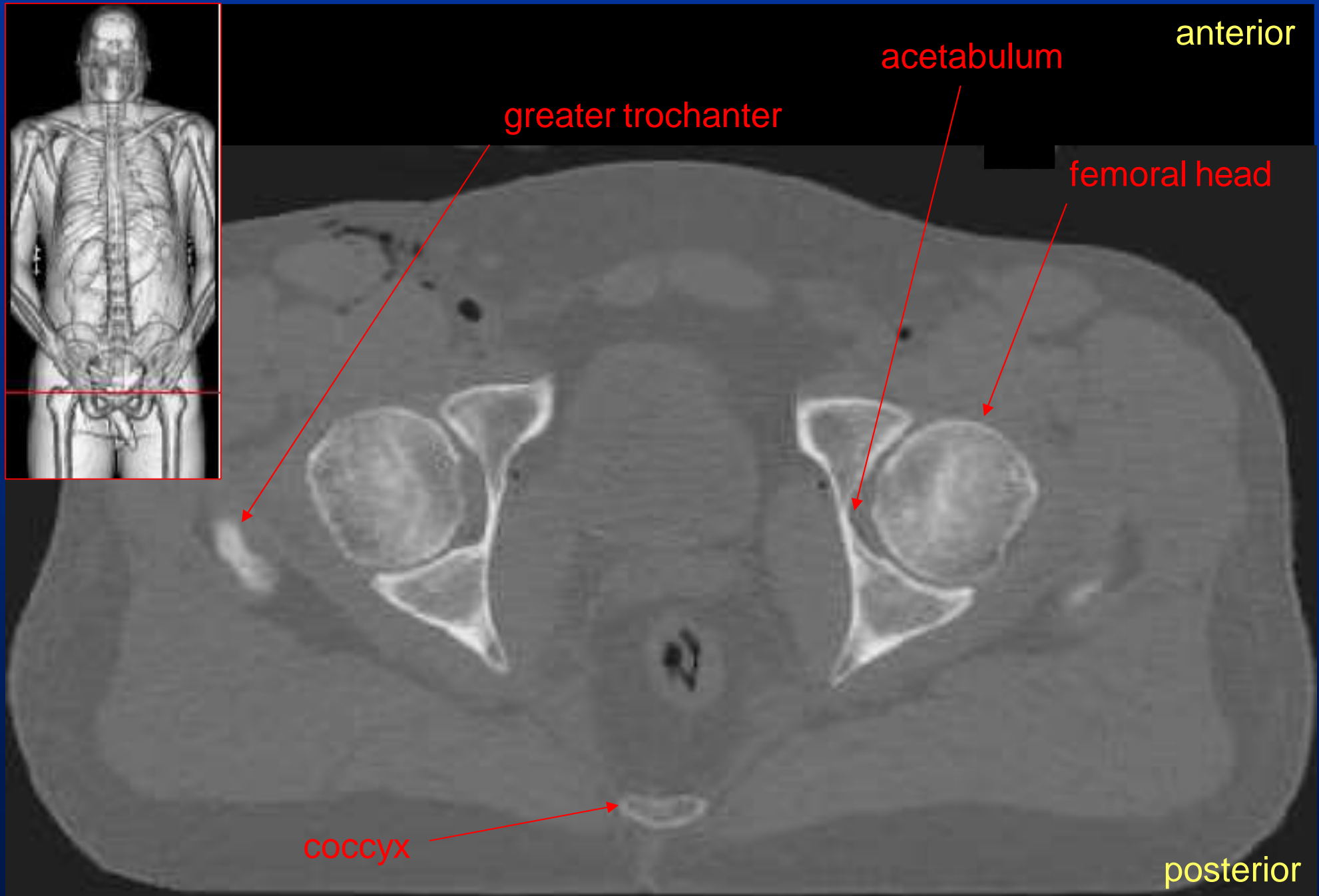


hint

Bonus: which muscle is responsible?

Sartorius

CT Imaging of the Hips: Axial View

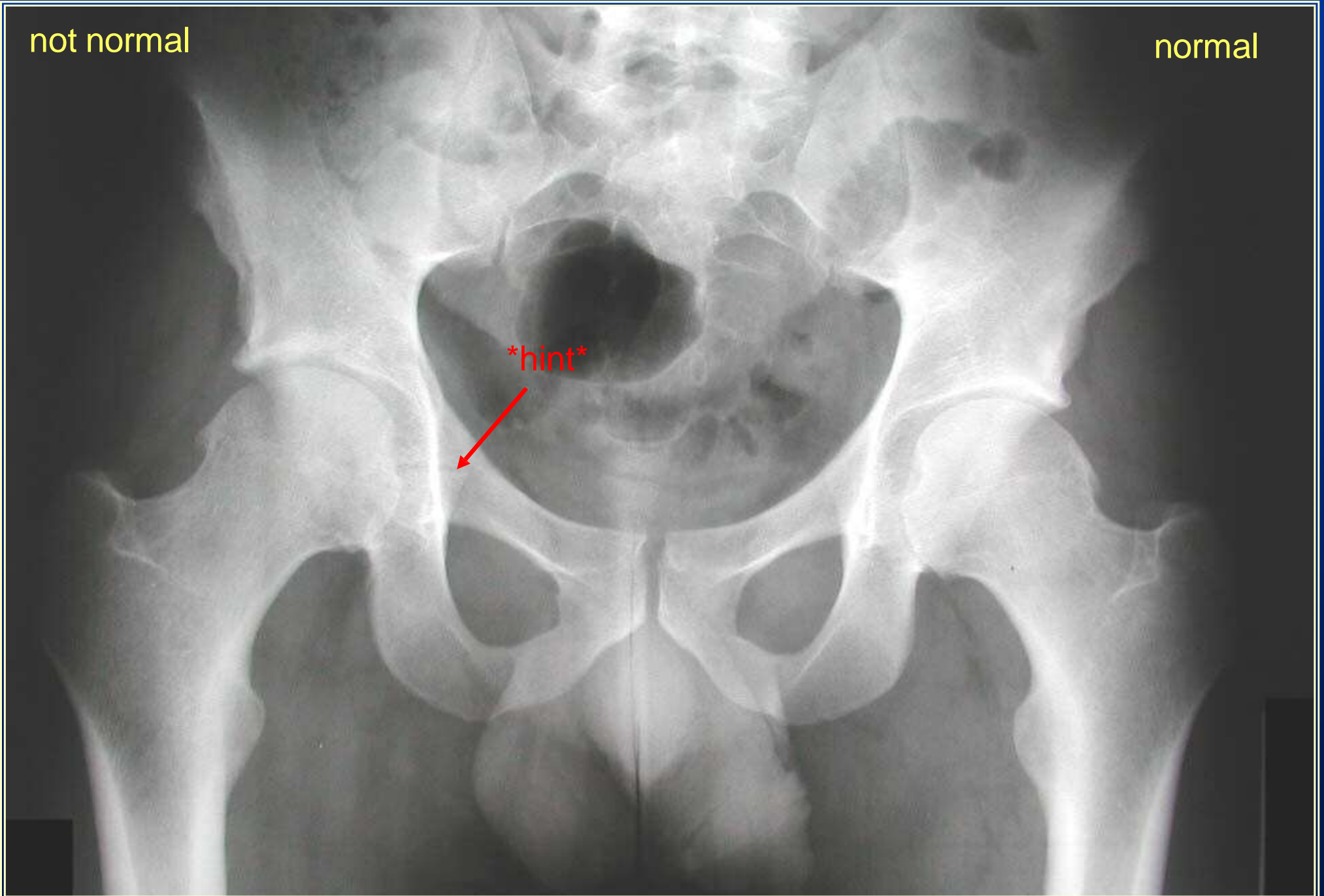


What's Wrong With This Hip? (part 1)

not normal

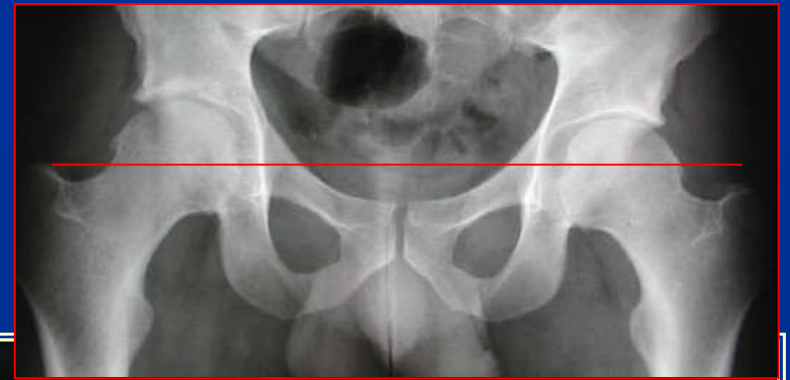normal

hint



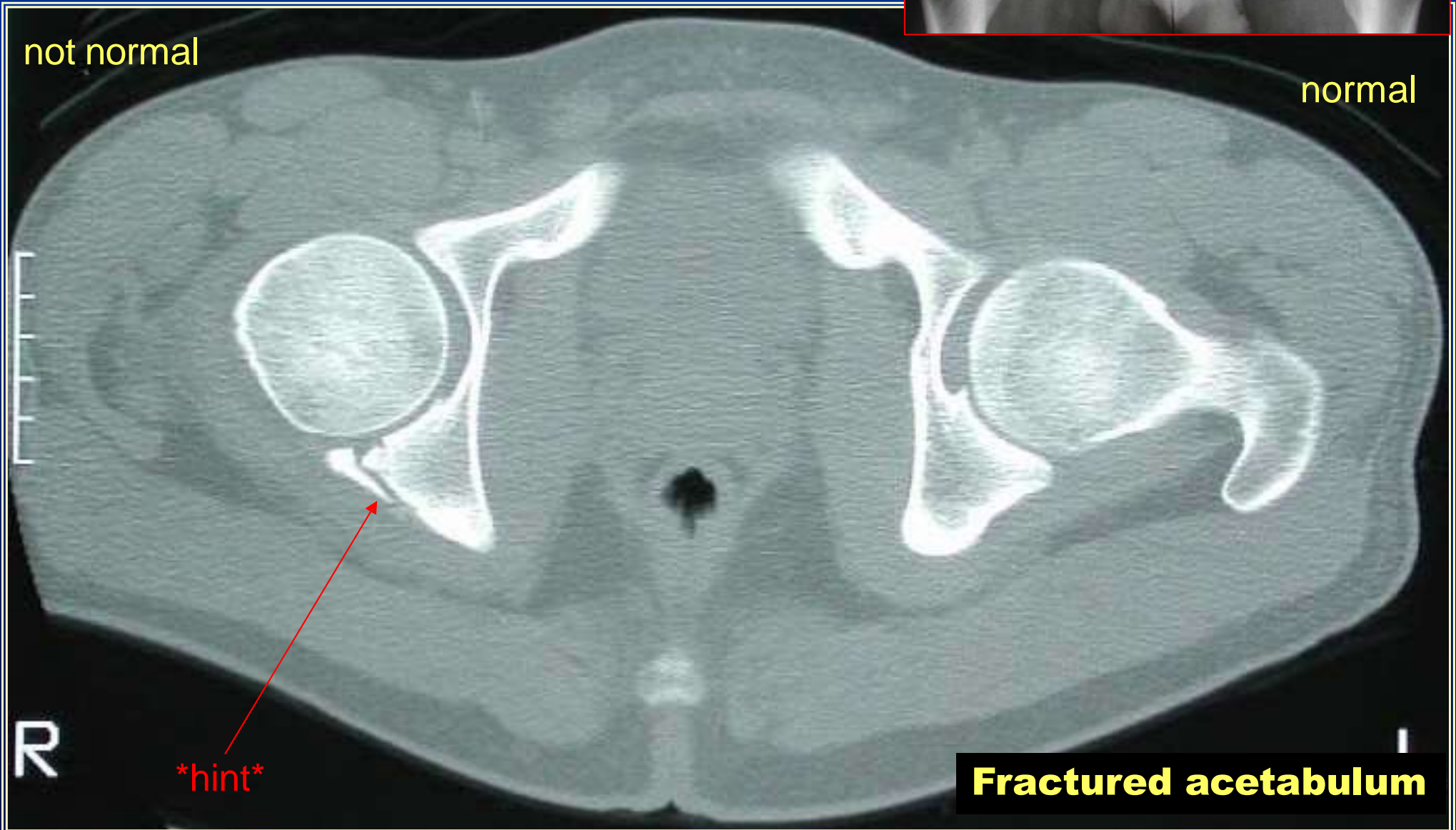
What's Wrong With This Hip? (part 2)

Axial CT Scan



not normal

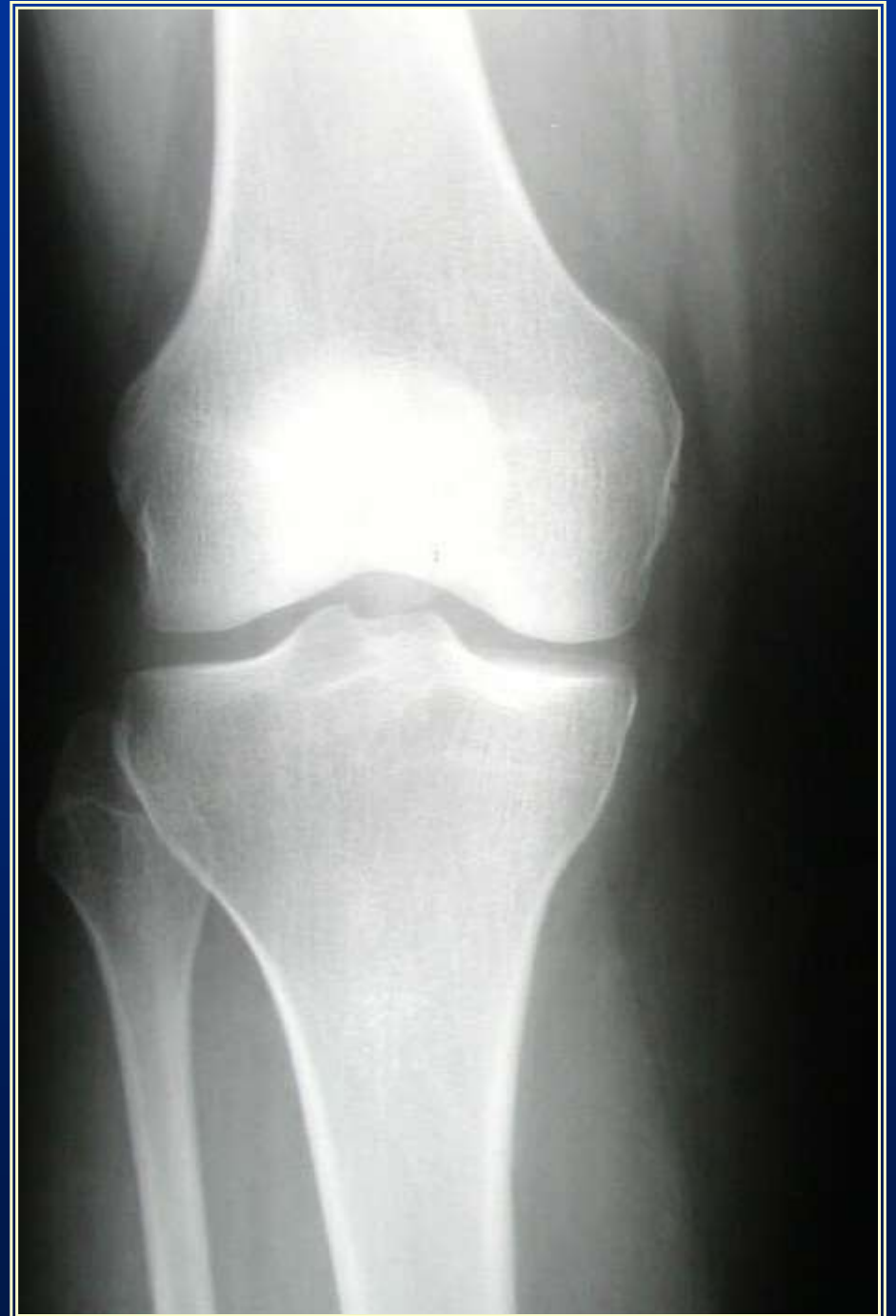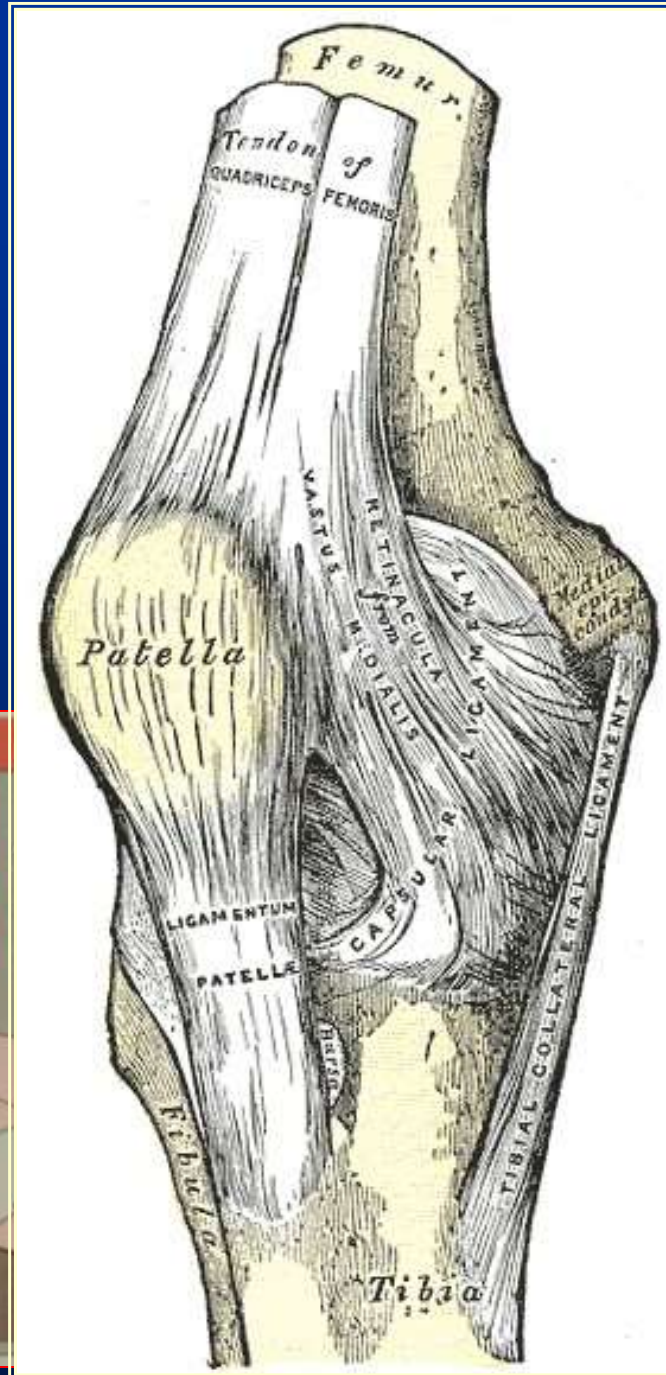
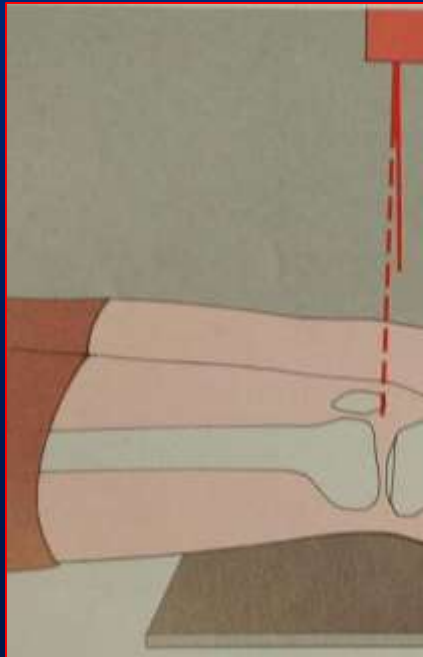
normal

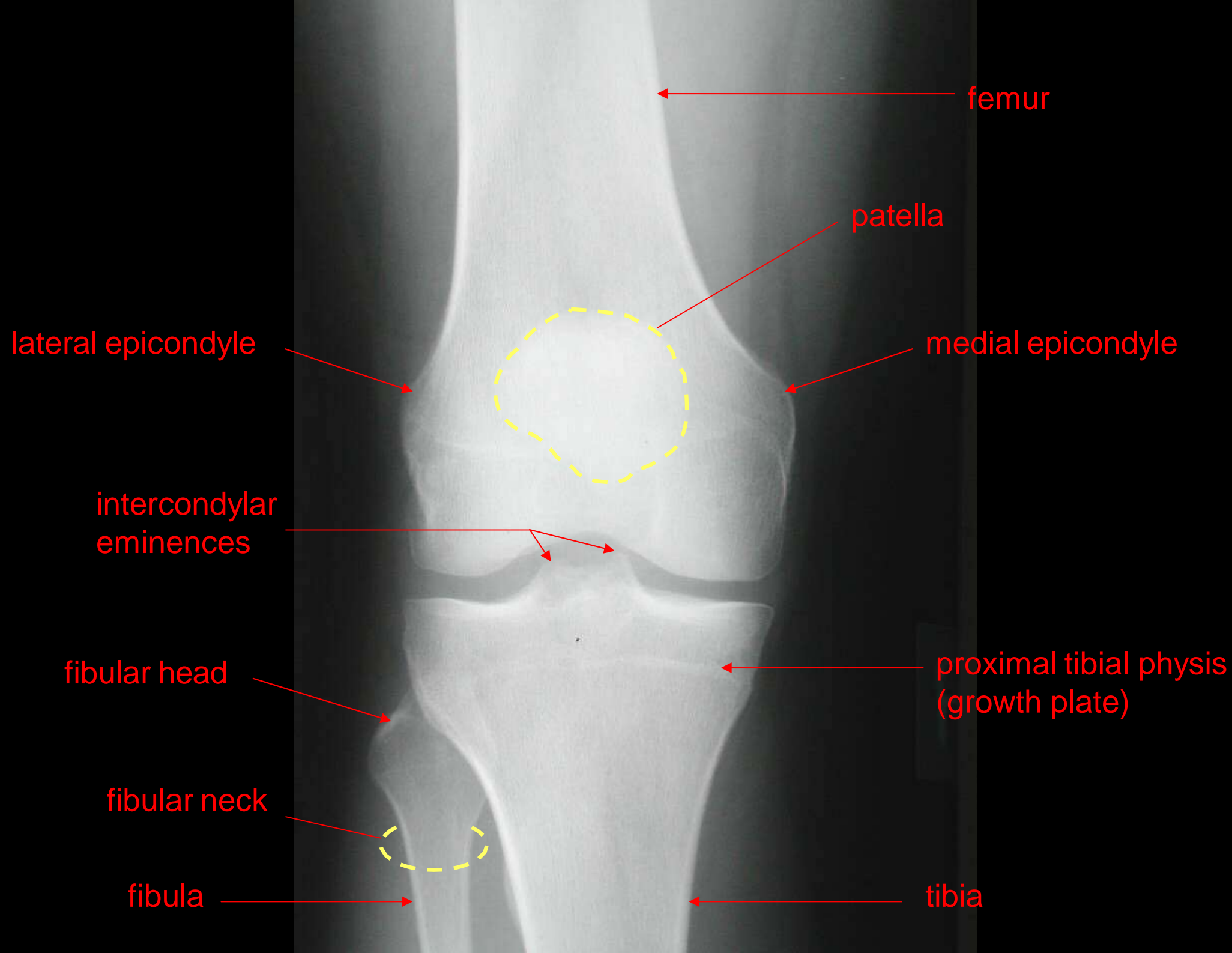


hint

Fractured acetabulum

A-P View of the Knee



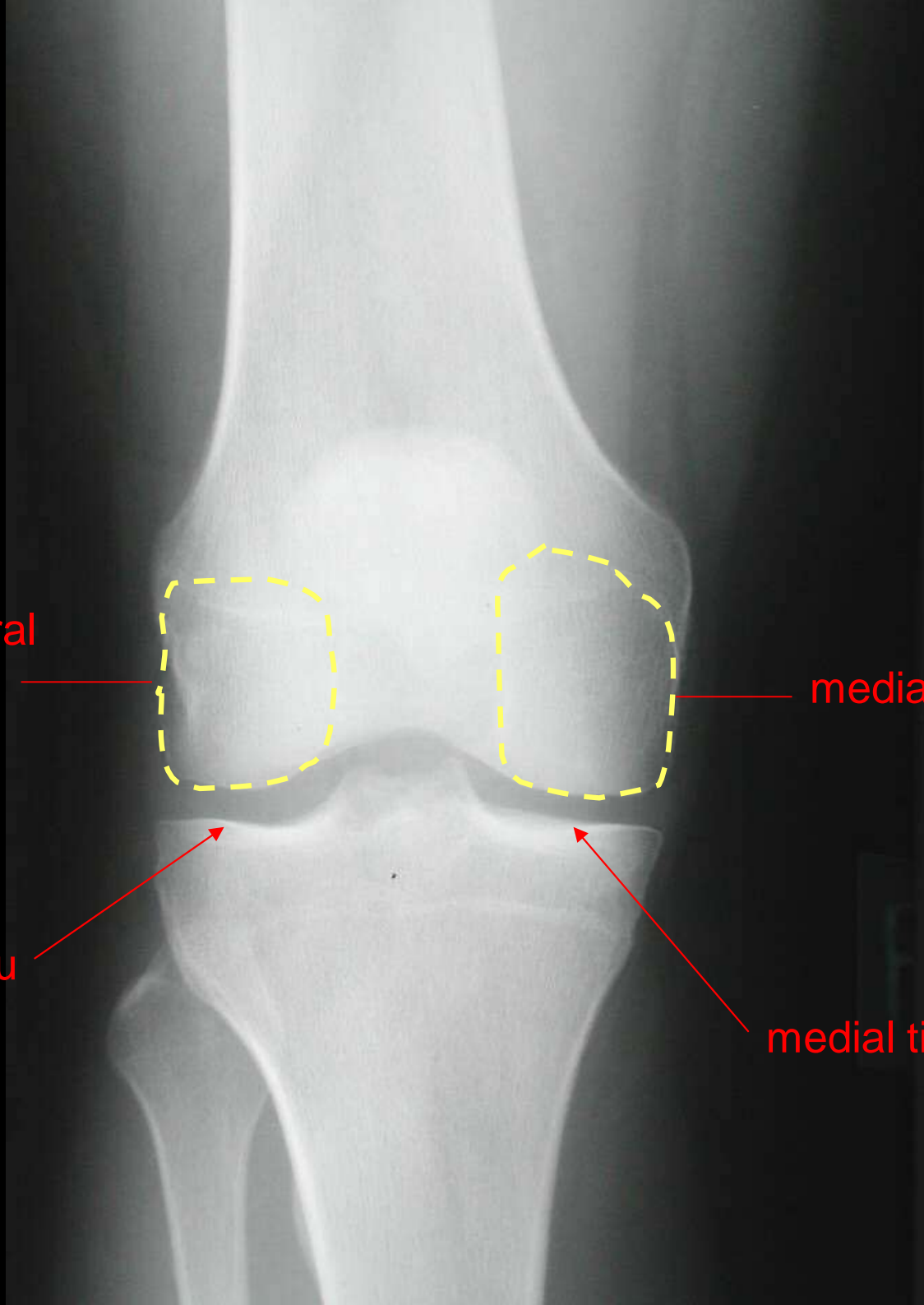


lateral femoral
condyle

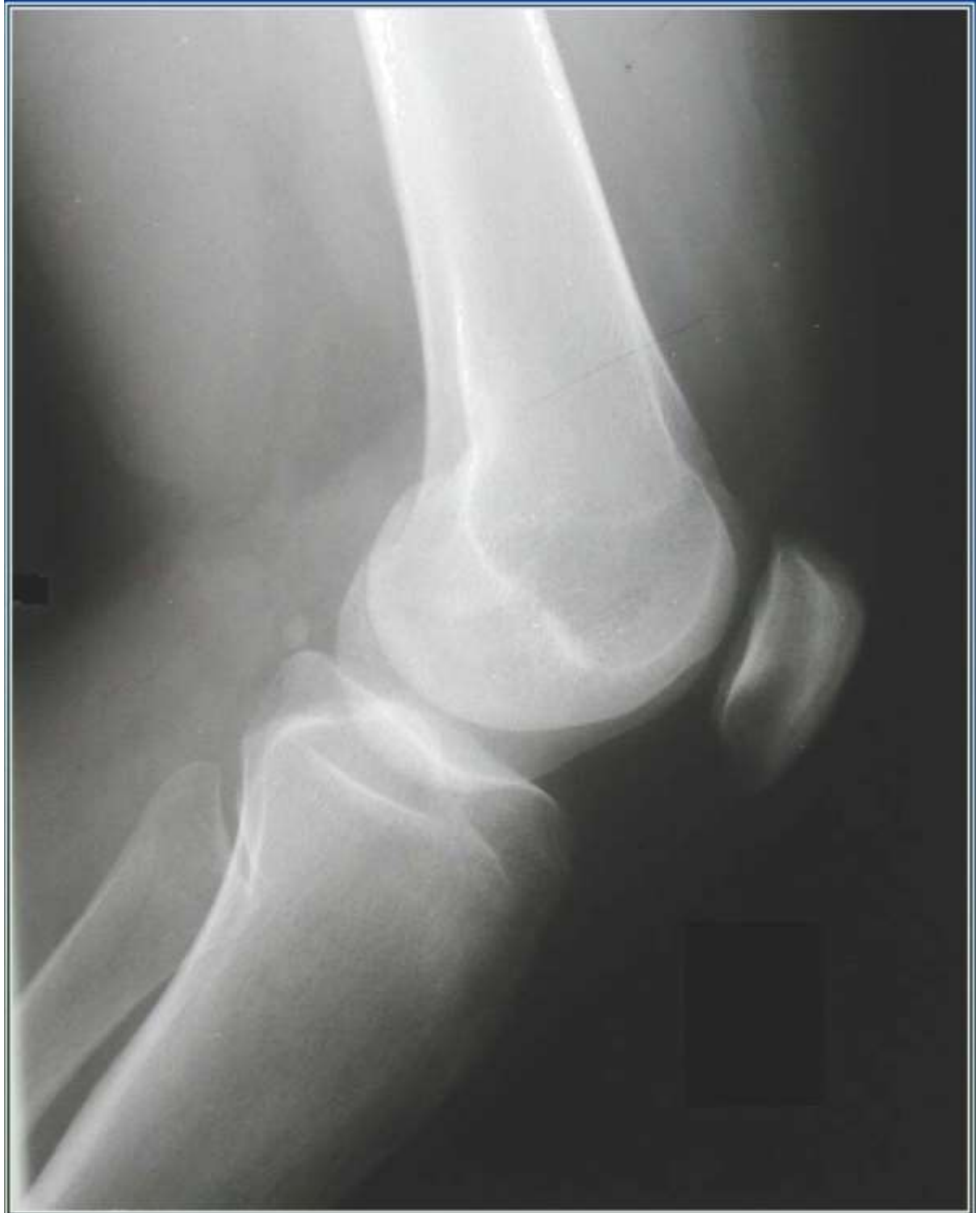medial femoral condyle

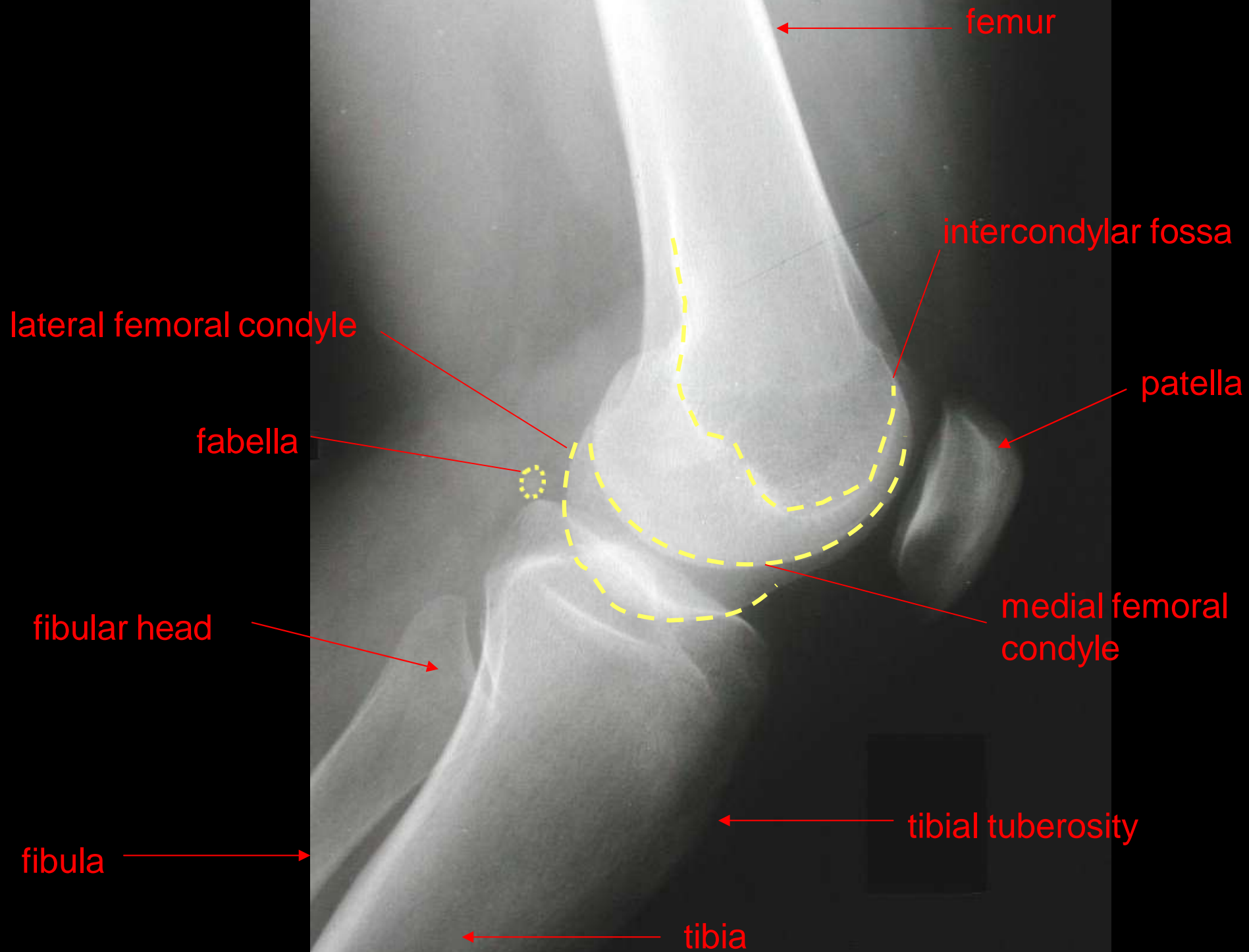
lateral tibial plateau

medial tibial plateau

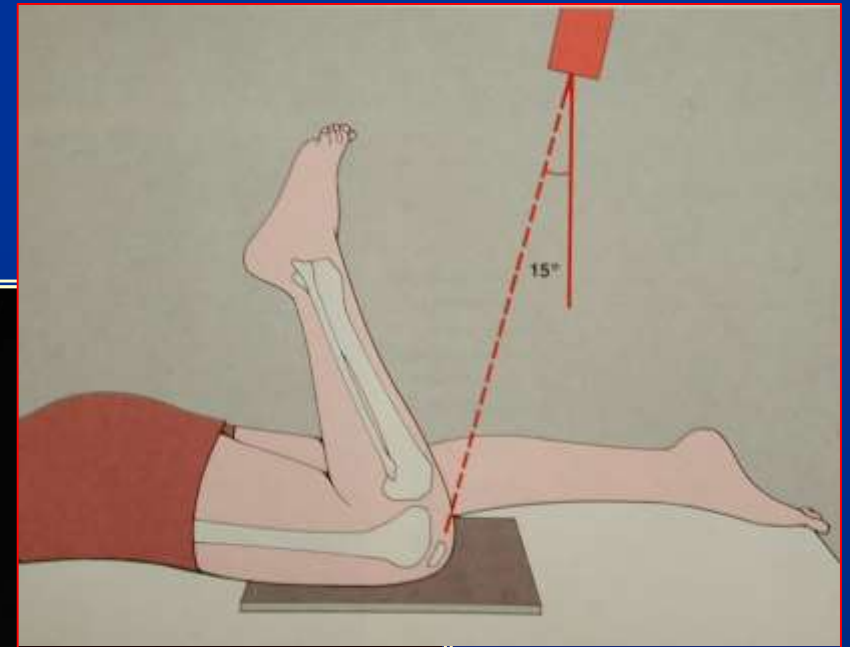
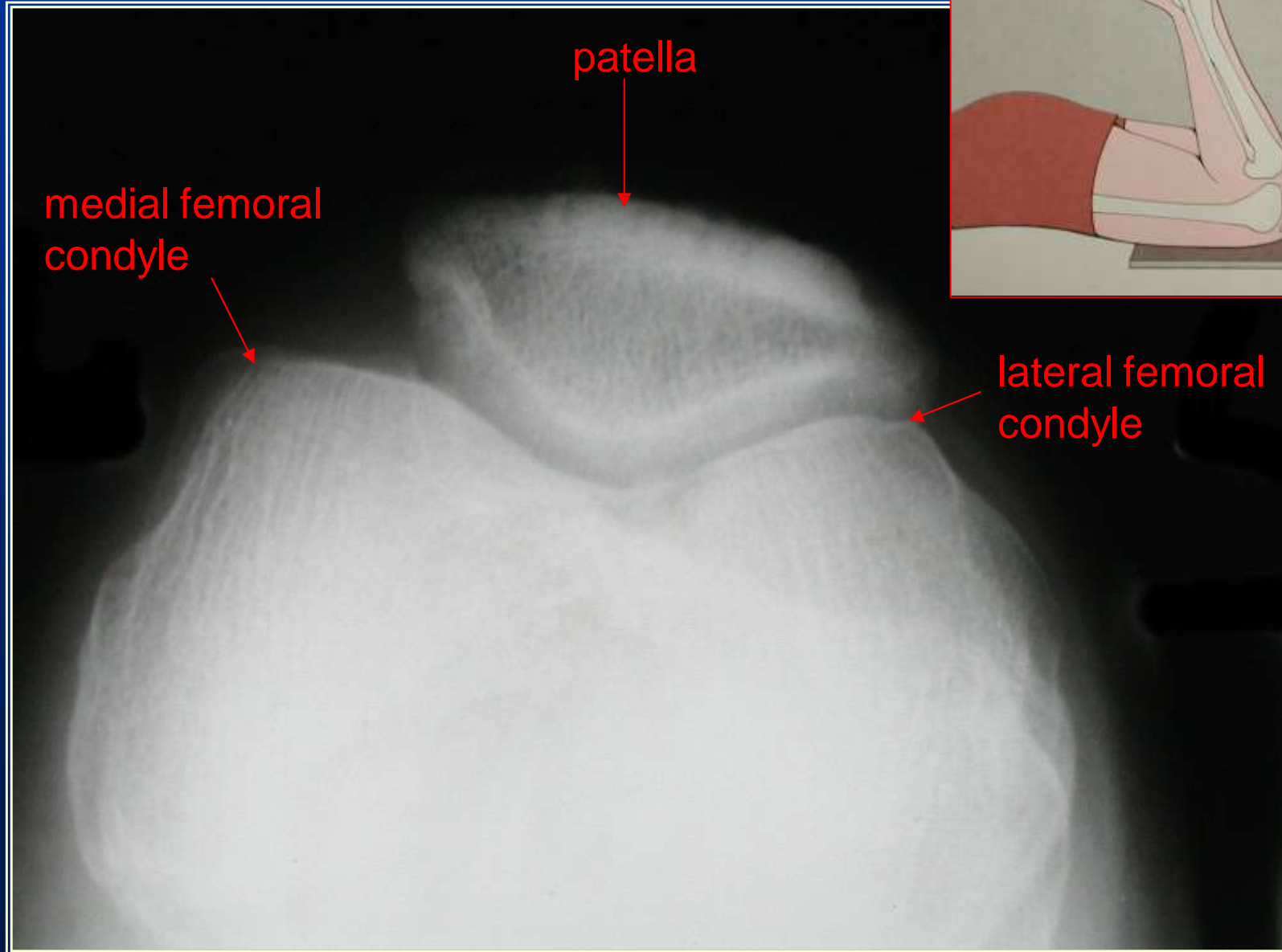


Lateral View of the Knee

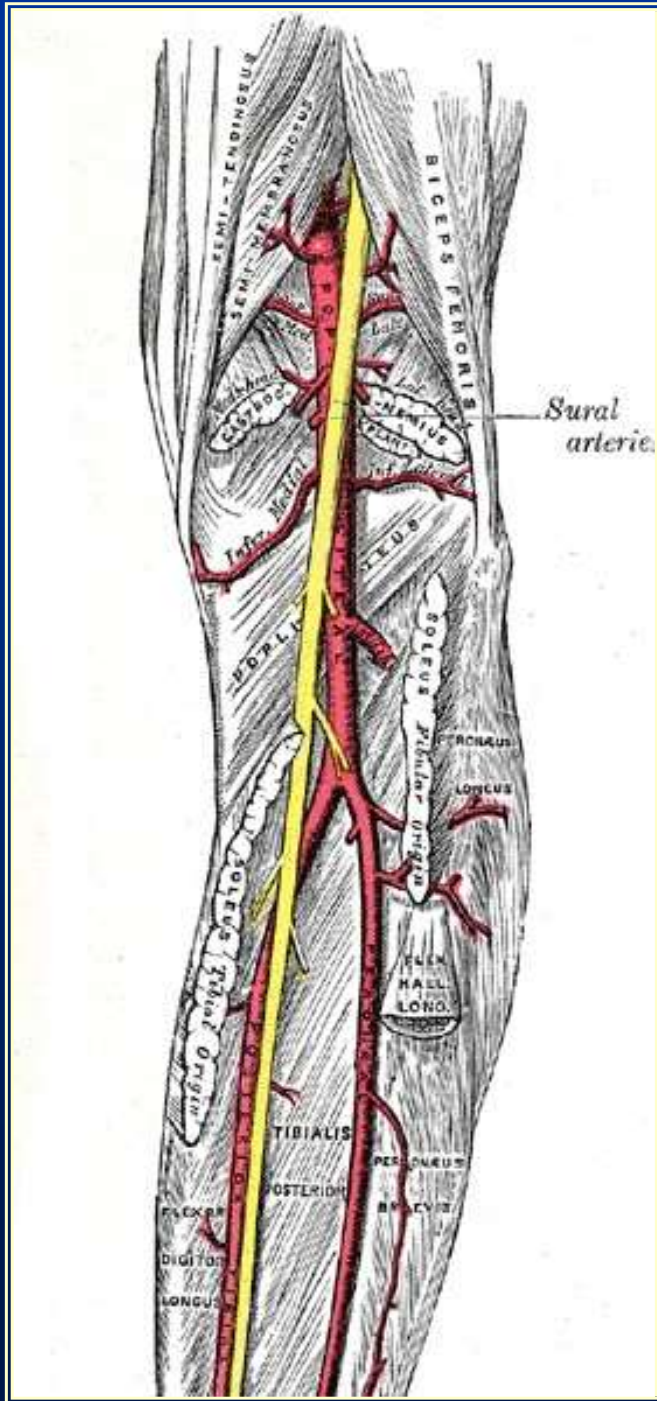




Skyline View of the Knee



Arteriogram of the Knee

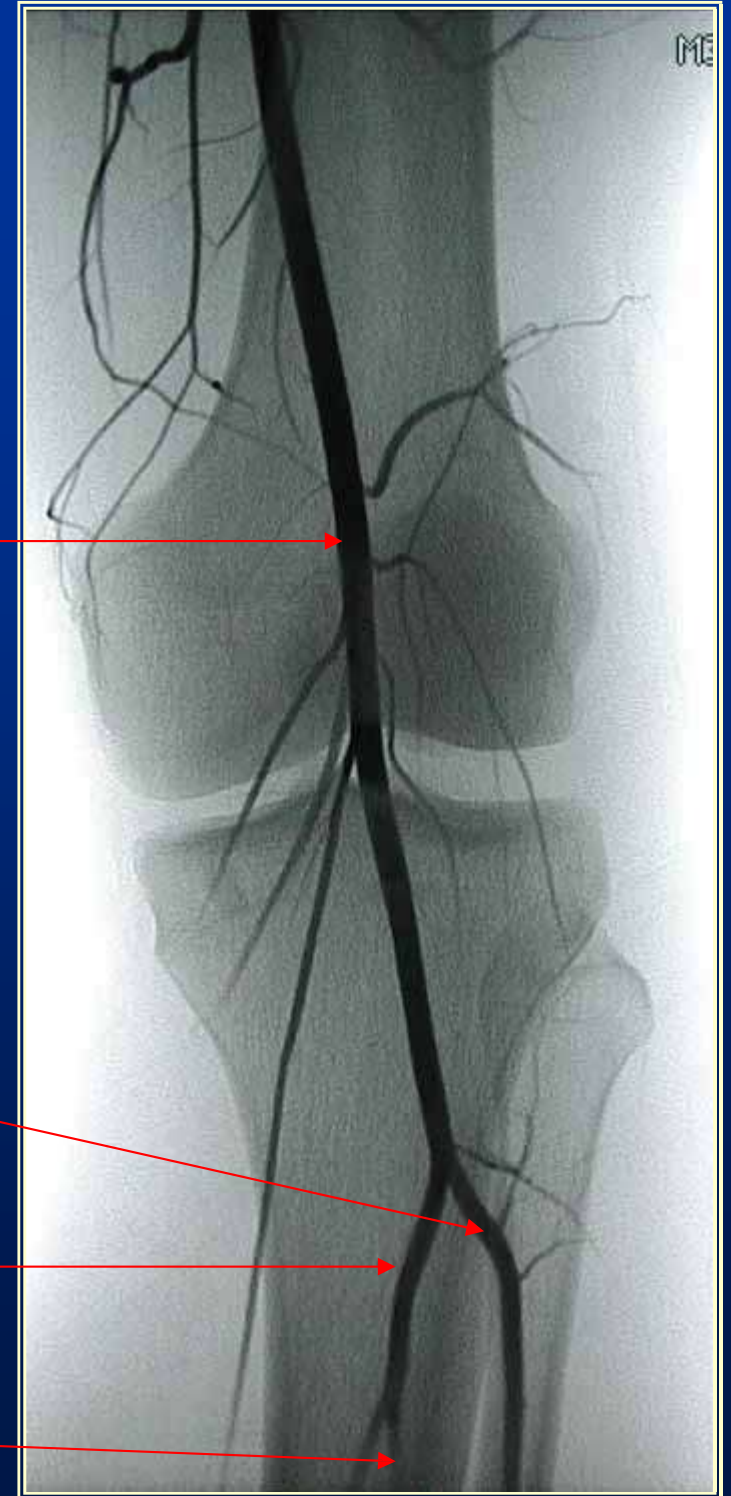


popliteal artery

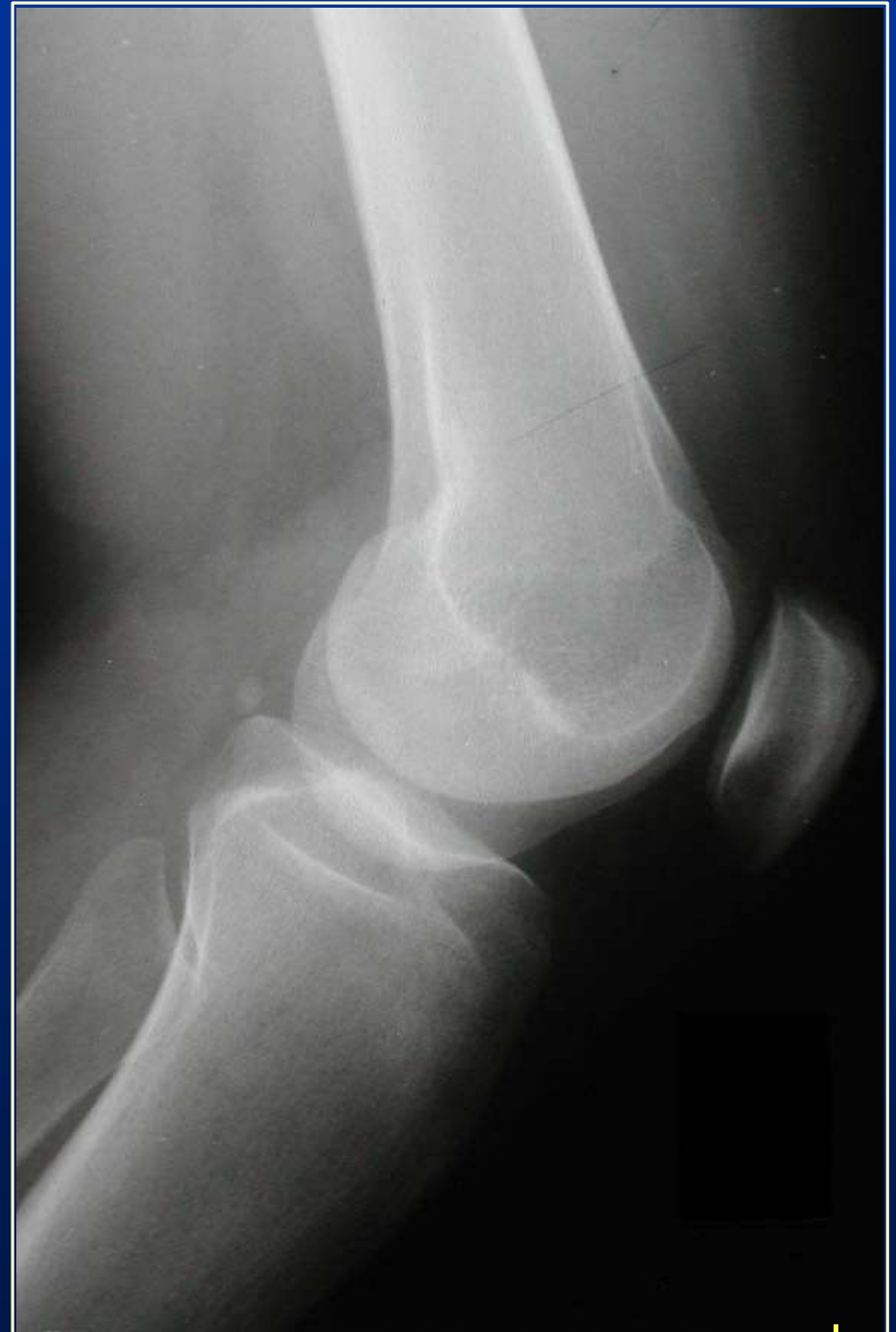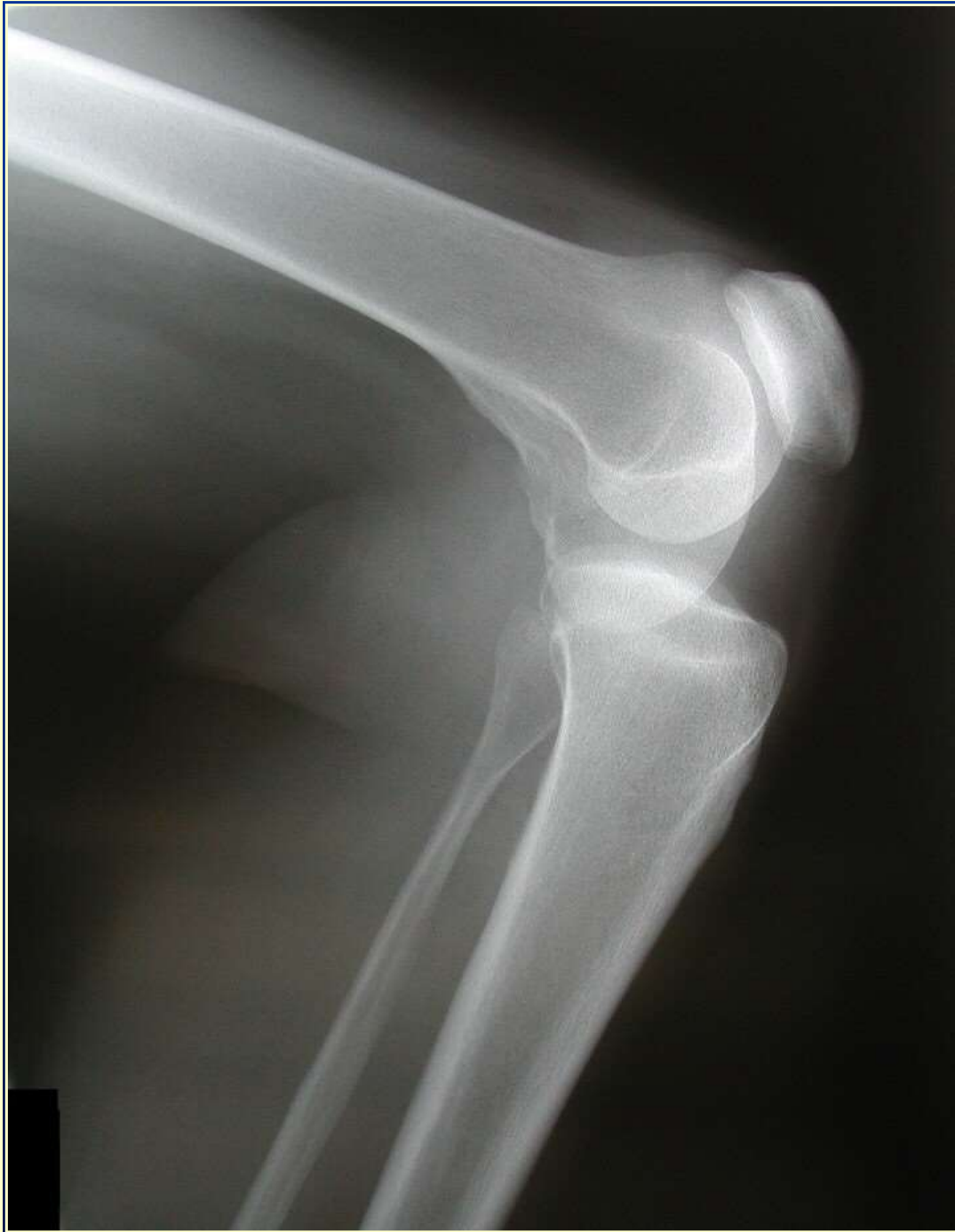anterior tibial artery

posterior tibial artery

common fibular a.



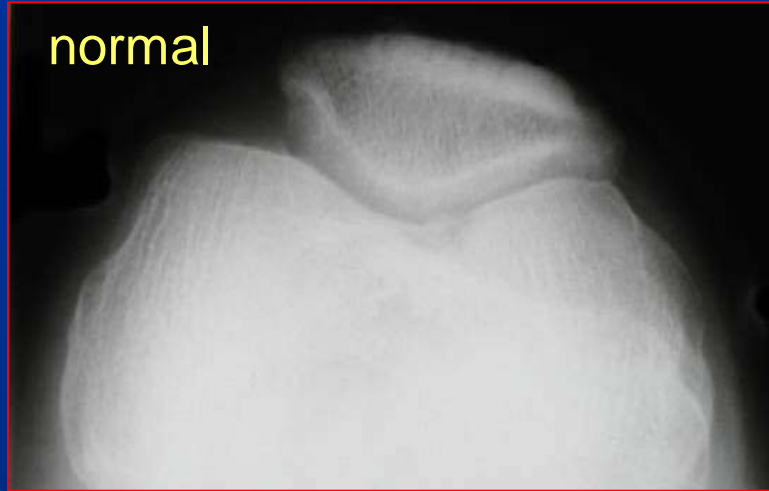What's Wrong With This Knee? (part 1)



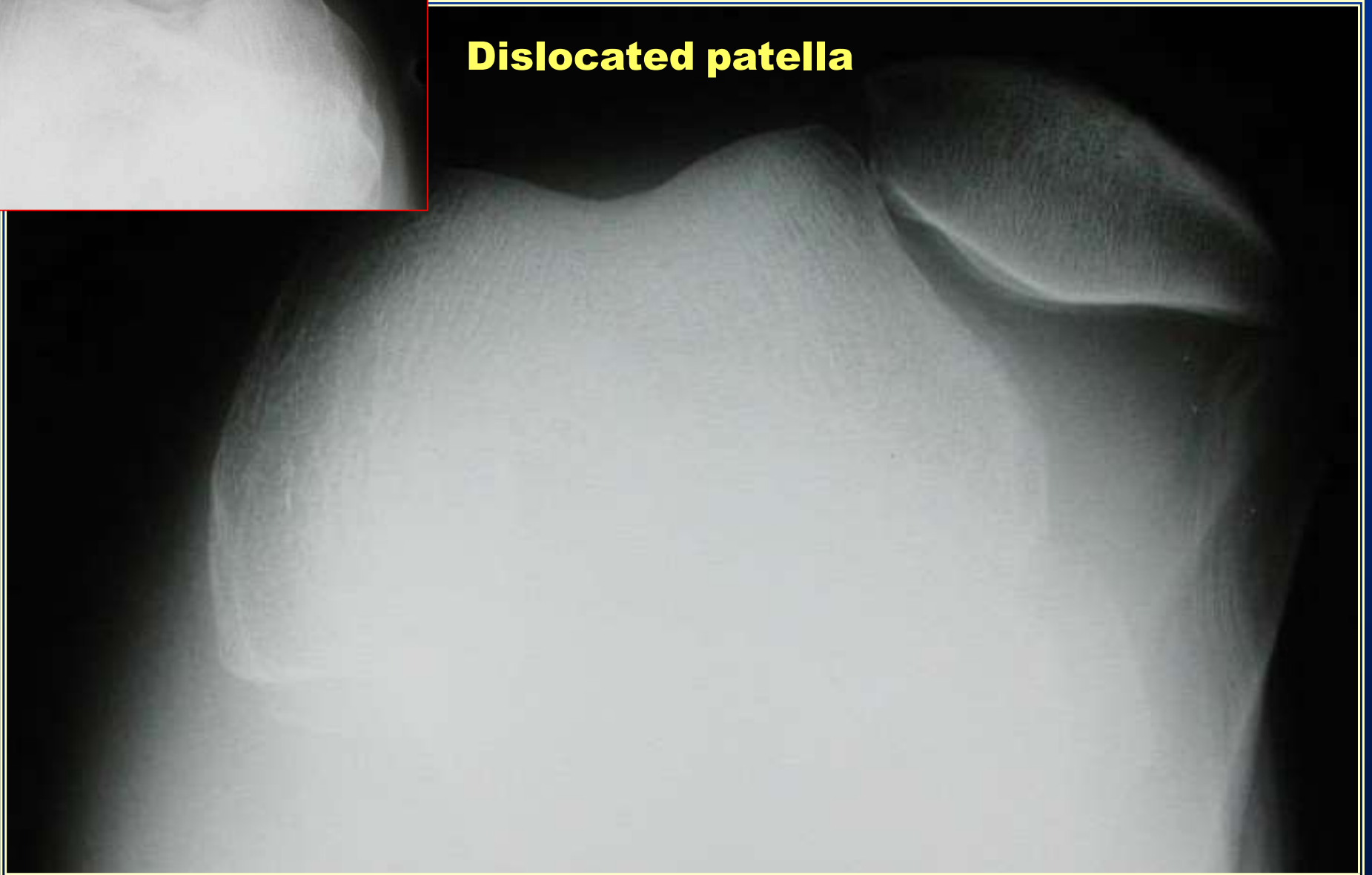
normal

What's Wrong With This Knee? (part 2)

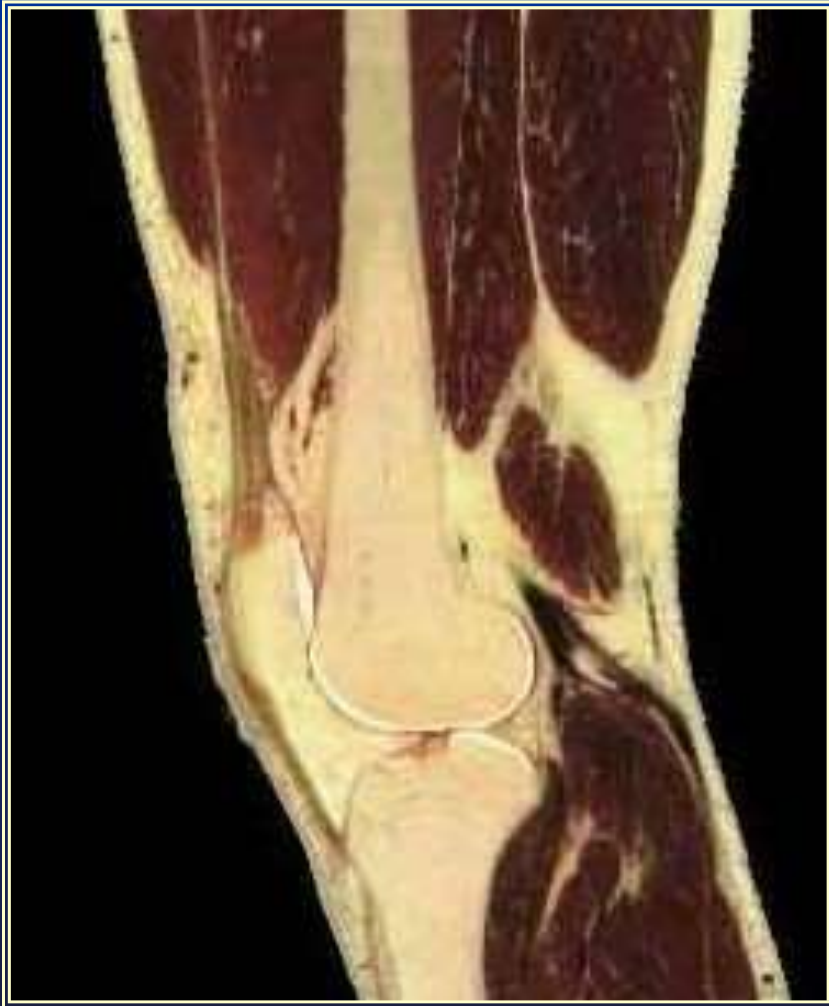normal



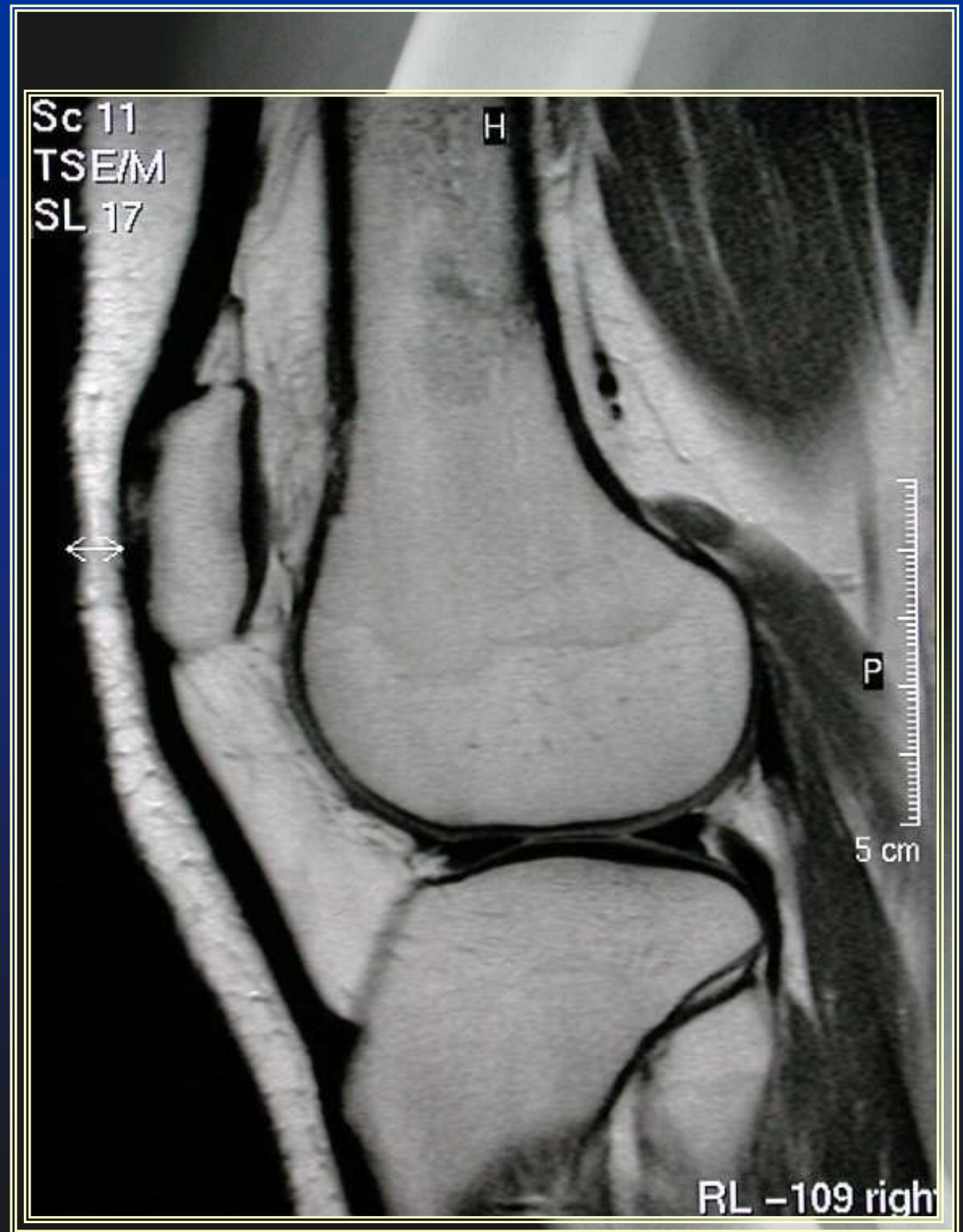
Dislocated patella



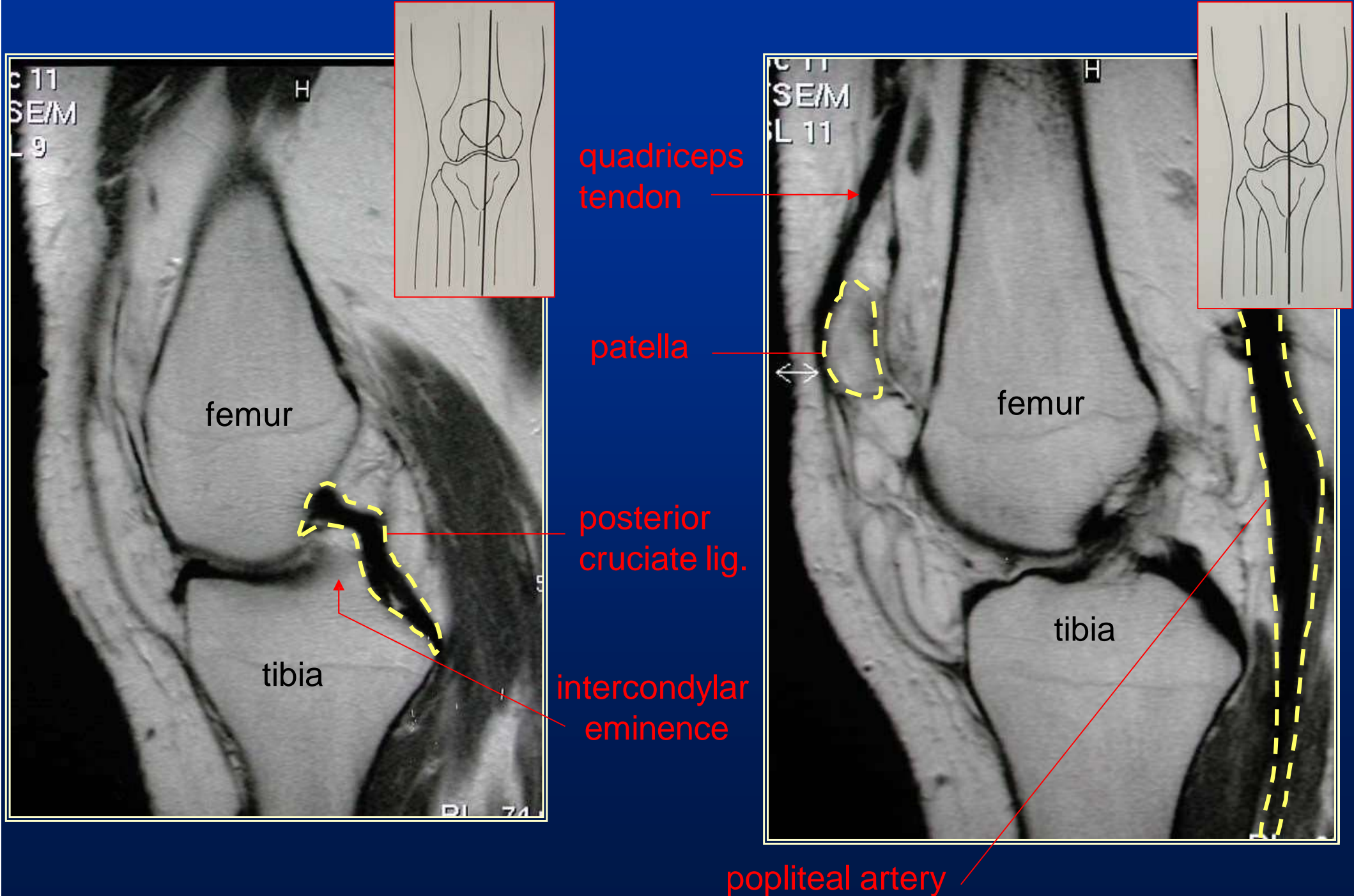
The Benefits of MRI

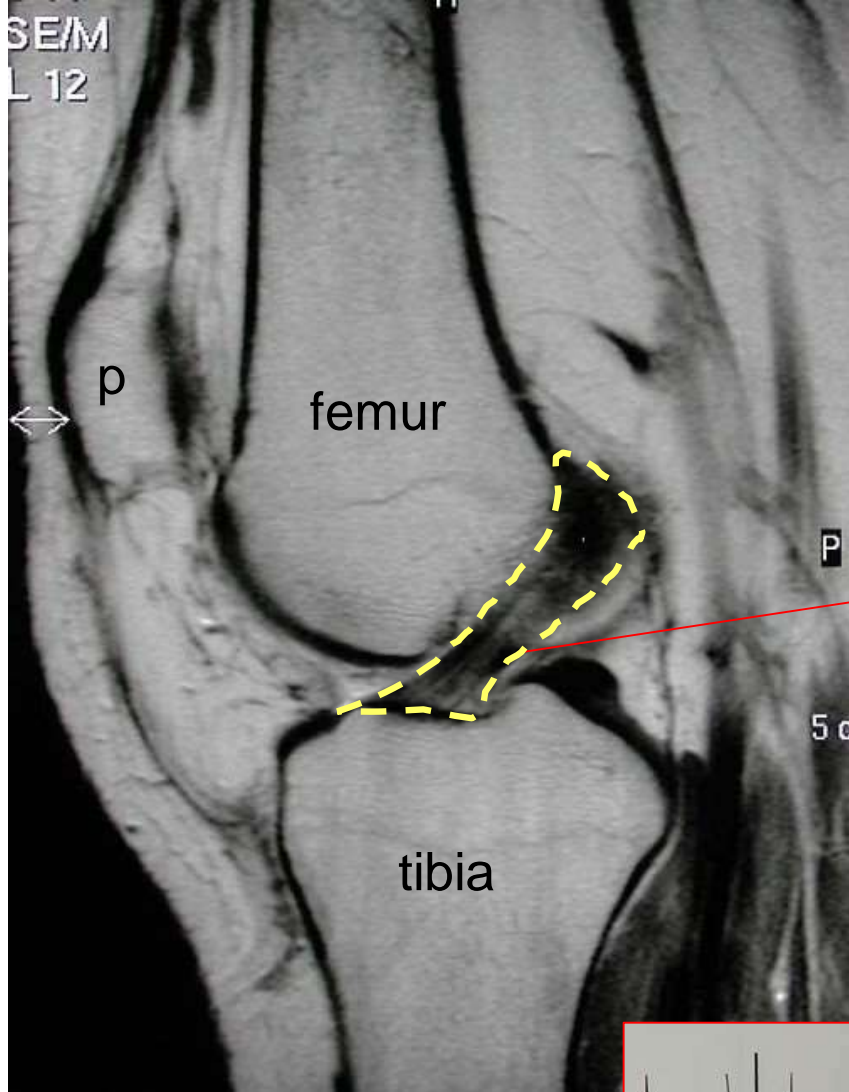


The ideal modality for imaging
soft tissues

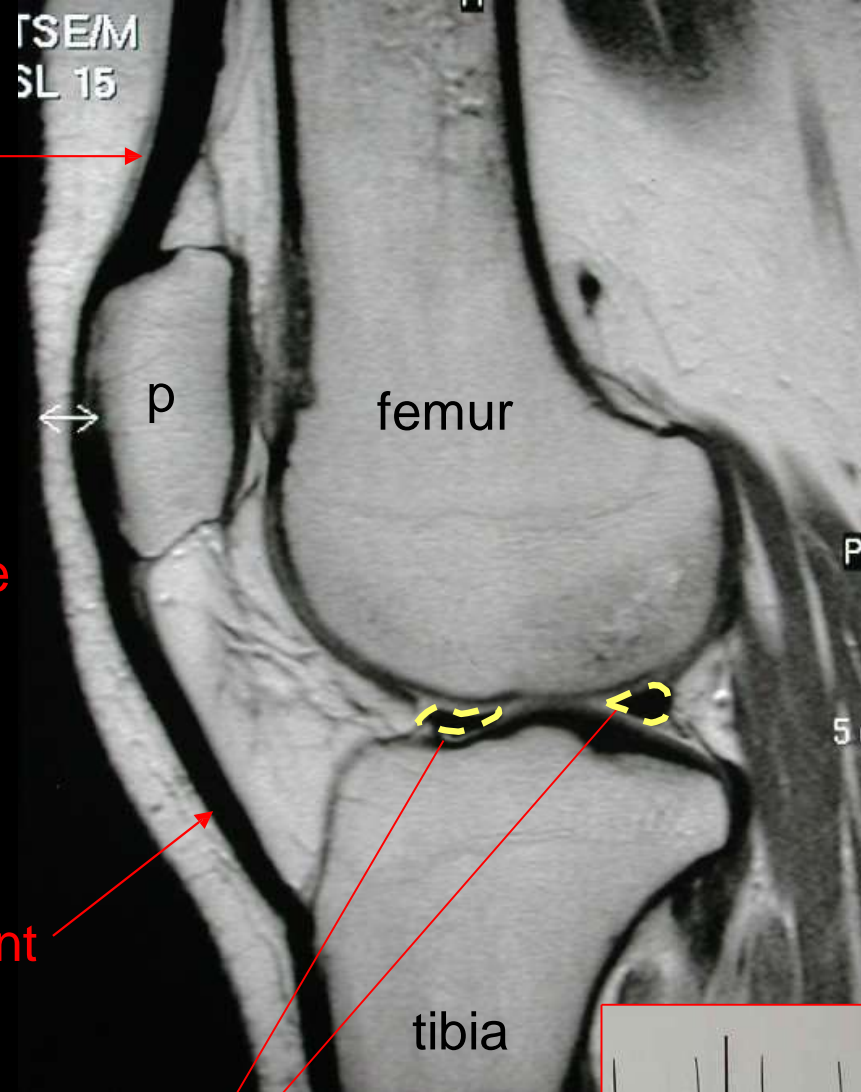


Magnetic Resonance Imaging of the Knee: Saggital Plane





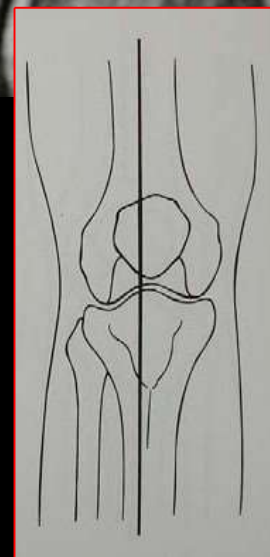
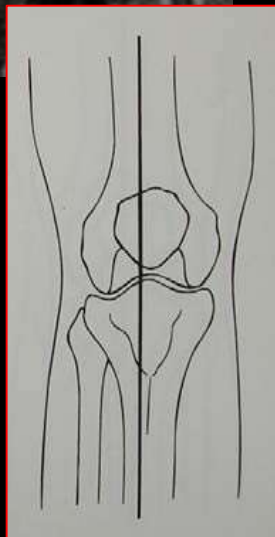
quadriceps
tendon



anterior cruciate
ligament

patellar ligament

lateral meniscus



MR Imaging of the Knee: Coronal Plane

medial

lateral

posterior cruciate
ligament

anterior cruciate lig.

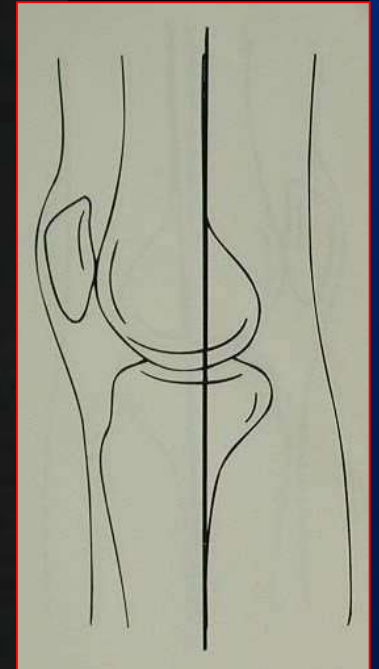
medial collateral
ligament

medial meniscus

lateral meniscus

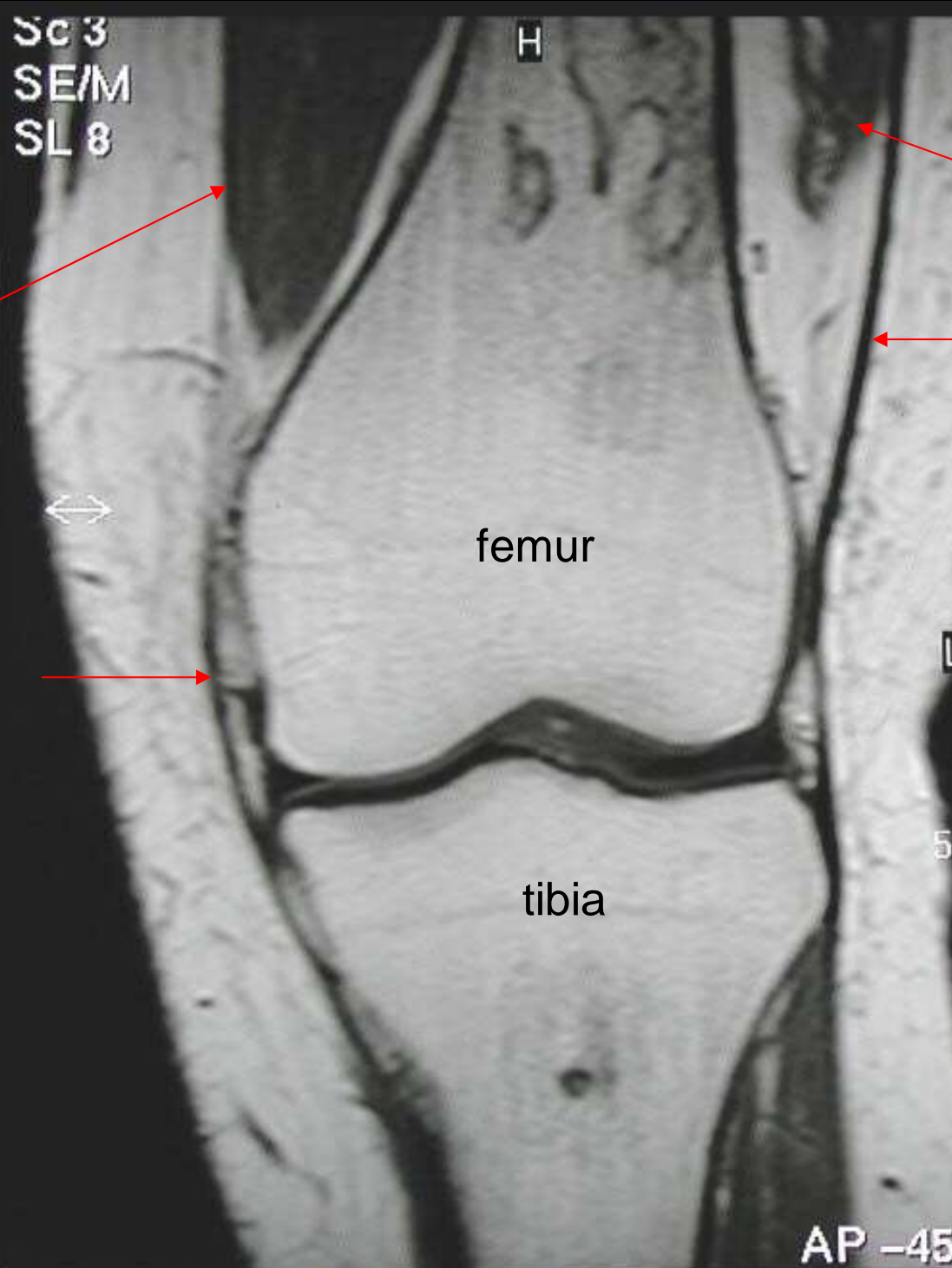
femur

tibia



medial

lateral

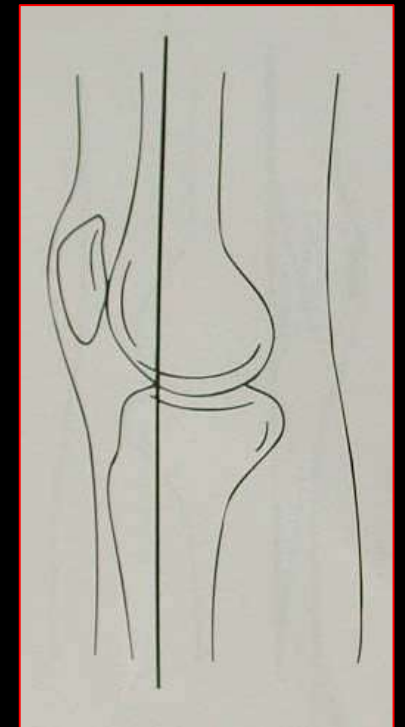


quadriceps muscle
(vastus medialis)

vastus lateralis

iliotibial band

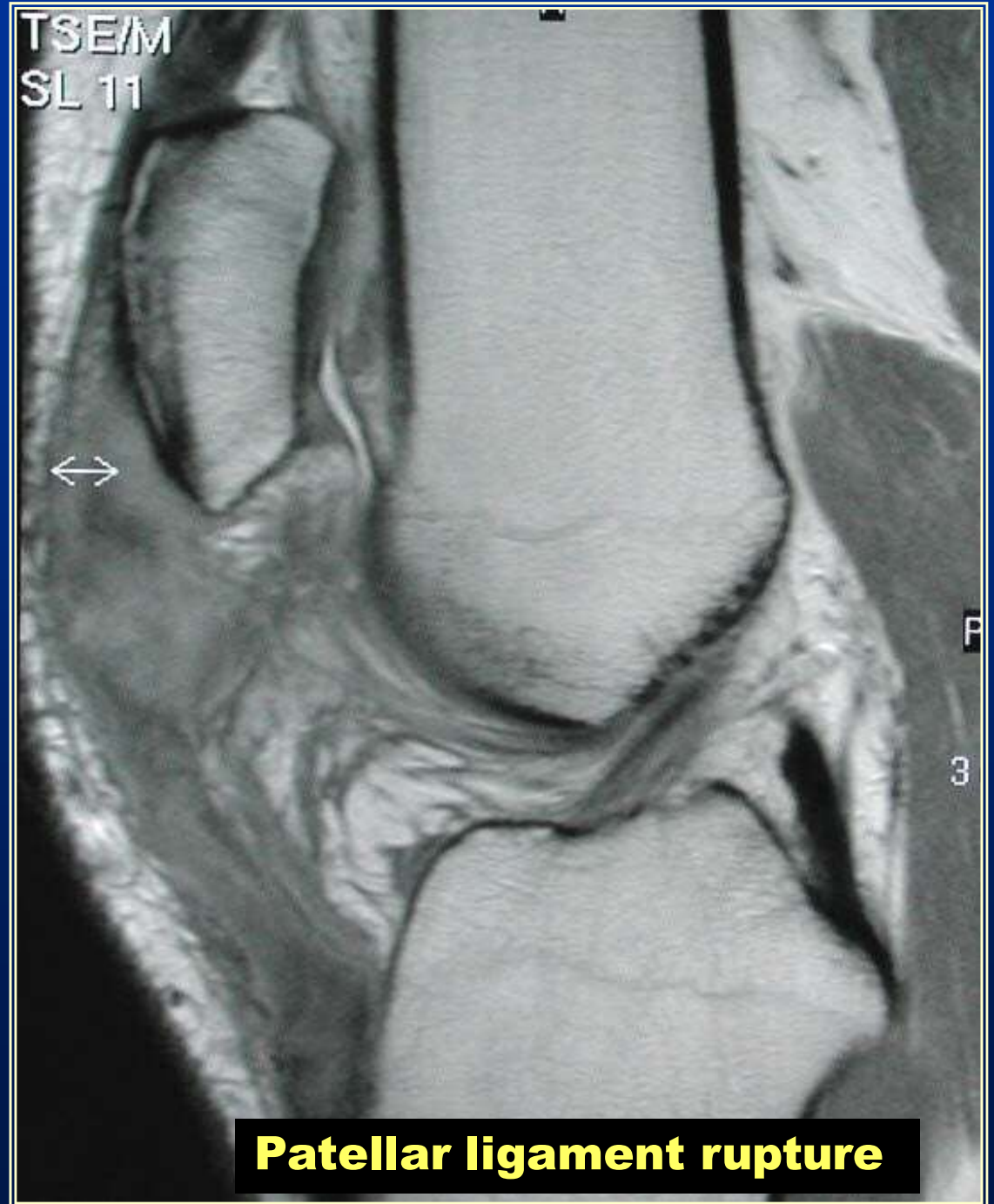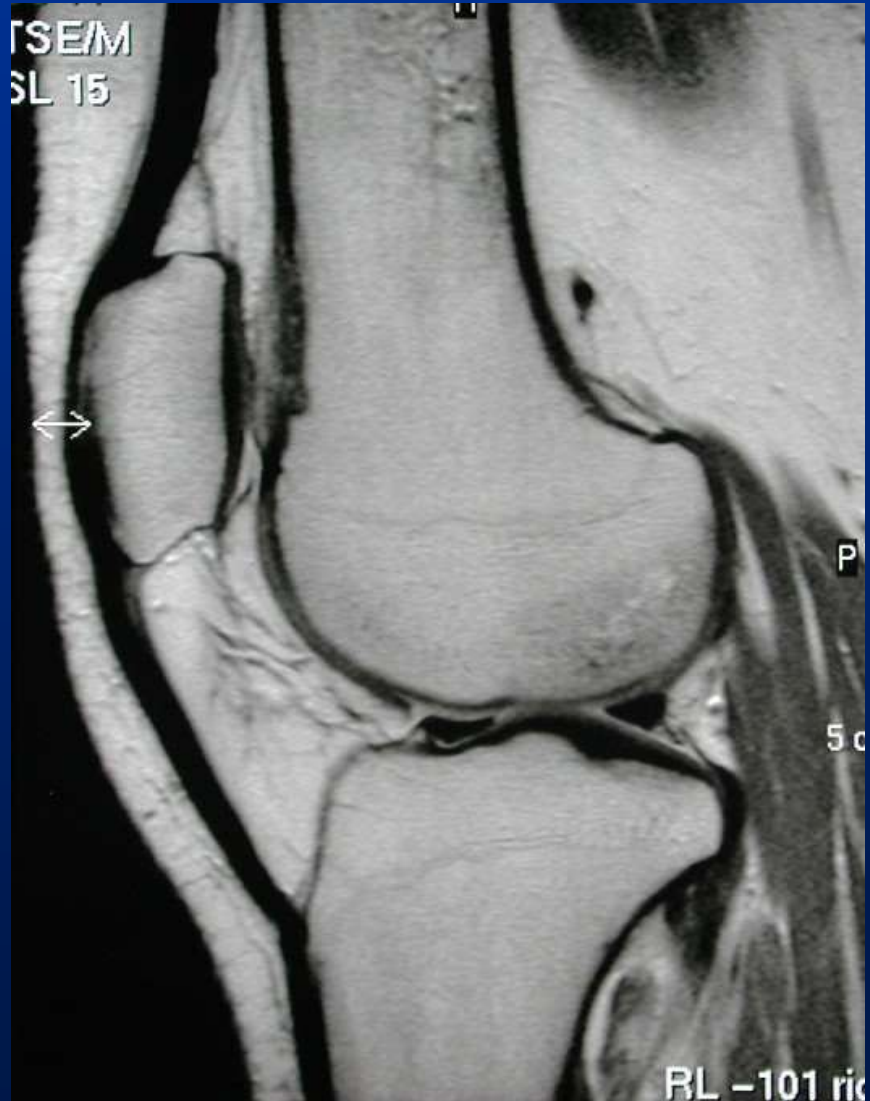medial collateral lig.



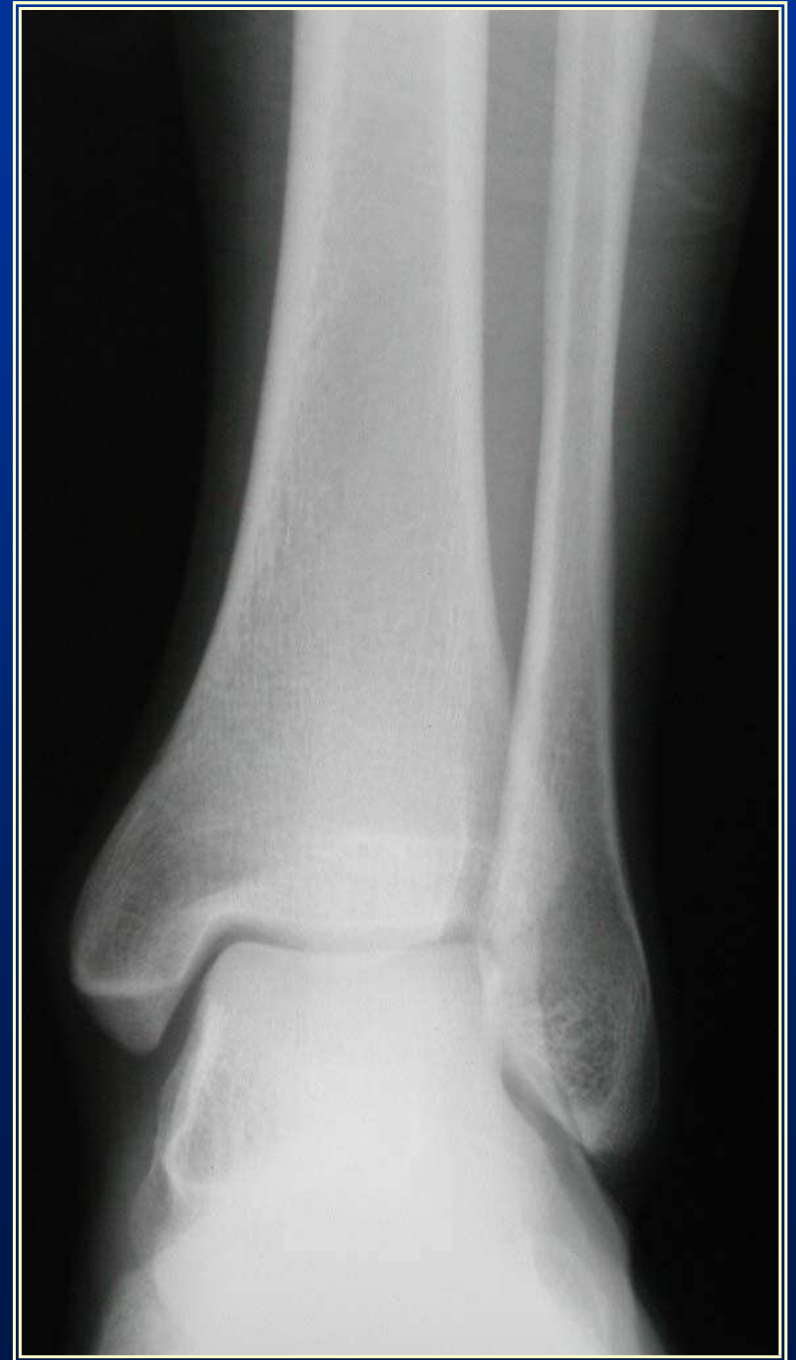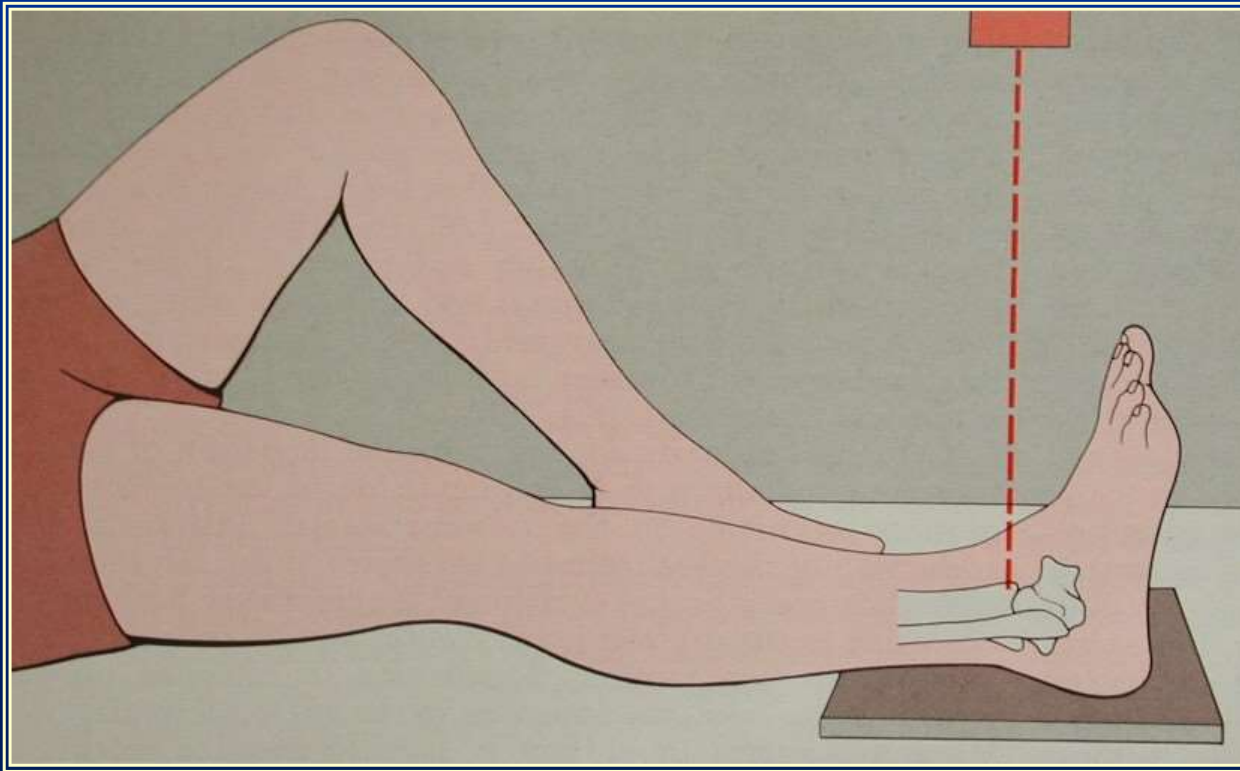
What's Wrong With This Knee?

Saggital MR images

normal



A-P View of the Leg and Ankle



tibia

fibula

location of interosseus
membrane

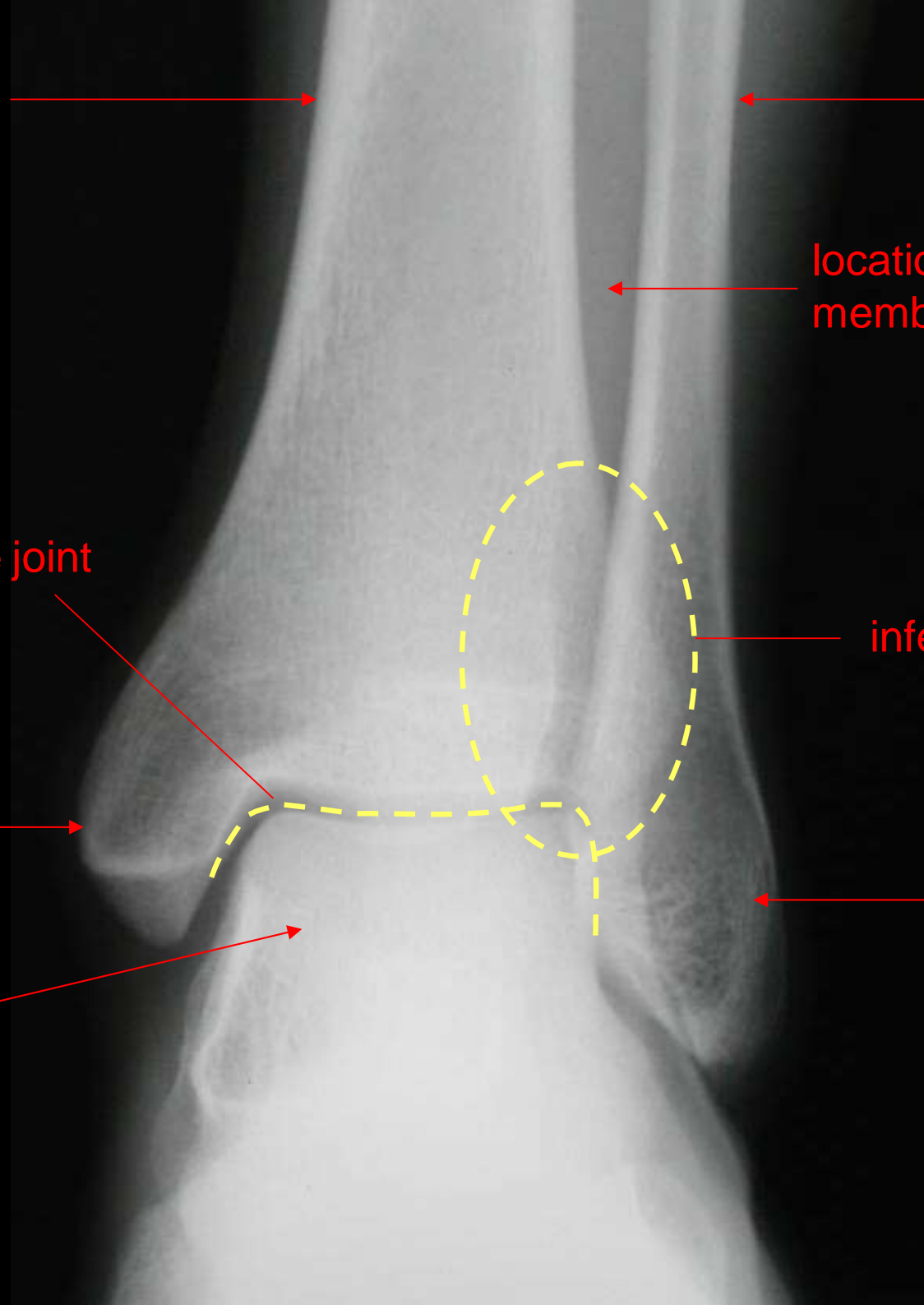
ankle joint

inferior tibiofibular joint

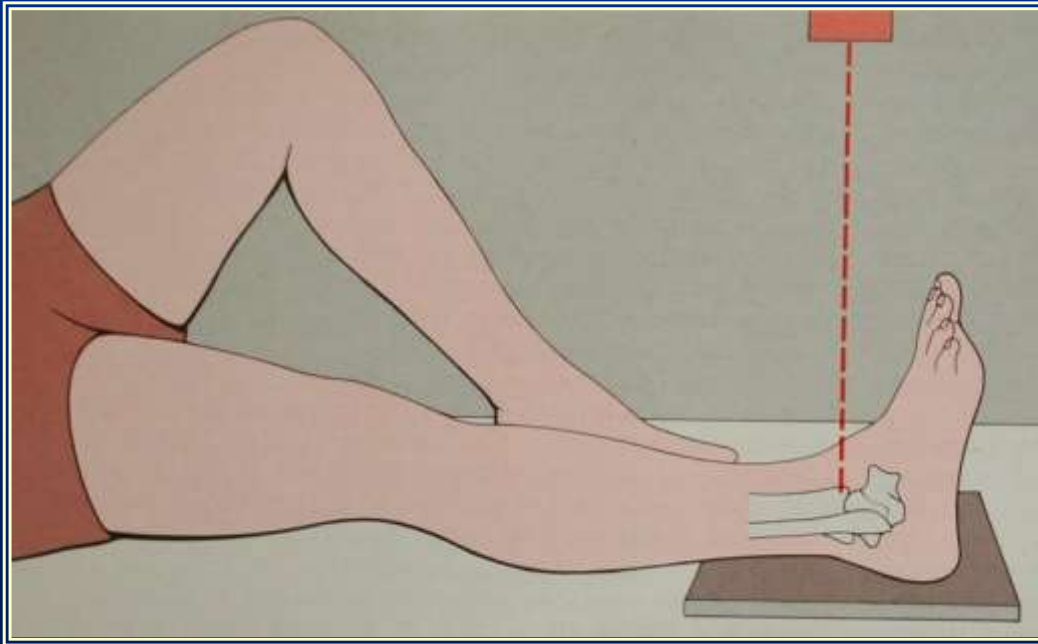
medial malleolus

lateral malleolus

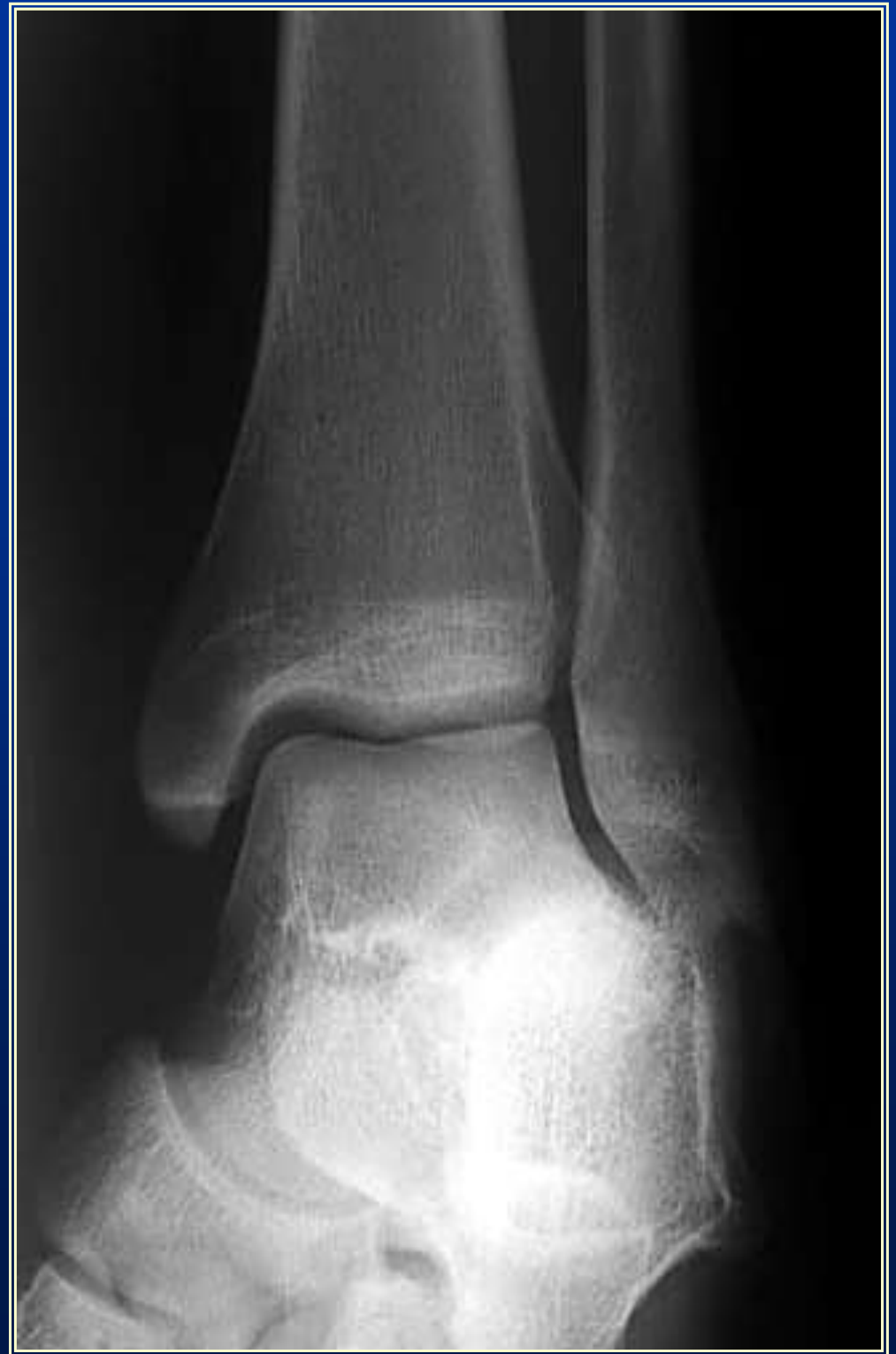talus



Mortice View of the Leg and Ankle



10 degrees internal rotation of ankle



Lateral View of the Leg and Ankle

